


Accepted Manuscript

DXA-derived hip shape is related to osteoarthritis: findings from in the MrOS cohort

Benjamin G. Faber, Denis Baird, Celia L. Gregson, Jenny S. Gregory, Rebecca J. Barr, Richard M. Aspden, John Lynch, Michael C. Nevitt, Nancy E. Lane, Eric Orwoll, Jonathan H. Tobias



PII: S1063-4584(17)31203-7

DOI: [10.1016/j.joca.2017.09.006](https://doi.org/10.1016/j.joca.2017.09.006)

Reference: YJOCA 4089

To appear in: *Osteoarthritis and Cartilage*

Received Date: 15 January 2017

Revised Date: 16 August 2017

Accepted Date: 11 September 2017

Please cite this article as: Faber BG, Baird D, Gregson CL, Gregory JS, Barr RJ, Aspden RM, Lynch J, Nevitt MC, Lane NE, Orwoll E, Tobias JH, for the Osteoporotic Fractures in Men (MrOS) Study Research Group, DXA-derived hip shape is related to osteoarthritis: findings from in the MrOS cohort, *Osteoarthritis and Cartilage* (2017), doi: [10.1016/j.joca.2017.09.006](https://doi.org/10.1016/j.joca.2017.09.006).

This is a PDF file of an unedited manuscript that has been accepted for publication. As a service to our customers we are providing this early version of the manuscript. The manuscript will undergo copyediting, typesetting, and review of the resulting proof before it is published in its final form. Please note that during the production process errors may be discovered which could affect the content, and all legal disclaimers that apply to the journal pertain.

1 DXA-derived hip shape is related to osteoarthritis: findings from in the MrOS cohort

2 Benjamin G. Faber¹, Denis Baird¹, Celia L. Gregson¹, Jenny S. Gregory², Rebecca J. Barr²,
3 Richard M. Aspden², John Lynch³, Michael C. Nevitt³, Nancy E. Lane⁴, Eric Orwoll⁵, Jonathan
4 H. Tobias¹, for the Osteoporotic Fractures in Men (MrOS) Study Research Group

5 ¹Musculoskeletal Research Unit, School of Clinical Sciences, University of Bristol, Southmead
6 Hospital, Bristol BS10 5NB, UK

7 ²Arthritis and Musculoskeletal Medicine, Institute of Medical Sciences, University of Aberdeen,
8 AB25 2ZD, UK

9 ³Department of Epidemiology and Biostatistics, University of California San Francisco,
10 California, USA

11 ⁴Department of Medicine, University of California Davis, Sacramento, California, USA

12 ⁵Division of Endocrinology, Oregon Health & Science University, Portland, USA

13 Corresponding author:

14 Benjamin Faber
15 Musculoskeletal Research Unit
16 Learning and Research Building
17 Southmead Hospital
18 Bristol BS10 5NB
19 Email: ben.faber@bristol.ac.uk
20 Telephone: 0117 414 7859

21 Key words: Hip shape, joint shape, active shape modeling

Co-author email addresses:

denis.baird@bristol.ac.uk
celia.gregson@bristol.ac.uk
j.gregory@abdn.ac.uk
r.y.barr@dundee.ac.uk
r.aspden@abdn.ac.uk
jlynch@psg.ucsf.edu
michael.nevitt@ucsf.edu
nelane@ucdavis.edu
orwoll@ohsu.edu
jon.tobias@bristol.ac.uk

1 **Abstract**

2 **Objective** Statistical shape modeling (SSM) of radiographs has been used to explore relationships
3 between altered joint shape and hip osteoarthritis (OA). We aimed to apply SSM to Dual-energy
4 X-ray Absorptiometry (DXA) hip scans, and examine associations between resultant hip shape
5 modes (HSMs), radiographic hip OA (RHOA), and hip pain, in a large population based cohort.

6 **Method** SSM was performed on baseline hip DXA scans from the Osteoporotic Fractures in Men
7 (MrOS) Study. Associations between the top ten HSMs, and prevalent RHOA from pelvic
8 radiographs obtained 4.6 years later, were analysed in 4100 participants. RHOA was defined as
9 Croft score ≥ 2 . Hip pain was based on pain on walking, hip pain on examination, and Western
10 Ontario and McMaster Universities Arthritis Index (WOMAC).

11 **Results** The five HSMs associated with RHOA showed features of either pincer- or cam-type
12 deformities. HSM 1 (increased pincer-type deformity) was positively associated with RHOA
13 [1.23 (1.09,1.39)] [odds ratio and 95% CI]. HSM 8 (reduced pincer-type deformity) was
14 inversely associated with RHOA [0.79 (0.70,0.89)]. HSM 10 (increased cam-type deformity)
15 was positively associated with RHOA [1.21 (1.07,1.37)]. HSM 3 and HSM 4 (reduced cam-type
16 deformity) were inversely associated with RHOA [0.73 (0.65,0.83) and 0.82 (0.73,0.93)
17 respectively]. HSM 3 was inversely related to pain on examination [0.84 (0.76,0.92)] and
18 walking [0.88, (0.81,0.95)], and to WOMAC score [0.87 (0.80,0.93)].

19 **Conclusions** DXA-derived measures of hip shape are associated with RHOA, and to a lesser
20 extent hip pain, possibly reflecting their role in the pathogenesis of hip OA.

21

1 **Introduction**

2 Hip osteoarthritis (OA) is an increasingly important cause of morbidity as the mean age of the
3 population increases (1). Identification of underlying risk factors may open up new avenues for
4 preventative strategies. One of the most important is abnormalities of hip development leading to
5 alterations in hip shape, exemplified by developmental dysplasia of the hip which is screened for
6 routinely in neonates (2, 3). More subtle alterations in hip shape have also been reported to be
7 associated with hip OA. For example, cam-type deformities, caused by extra bone growth around
8 the anterolateral aspect of the femoral head-neck junction resulting in a non-spherical femoral
9 head, leading to femoro-acetabular impingement (FAI) (4), are associated with premature onset
10 of OA (5, 6). FAI may also result from a pincer-type deformity where the acetabulum overhangs
11 and encroaches on the lateral aspect of the femoral head, for which currently there is
12 contradictory evidence in terms of associations with OA (2, 5).

13 In the above studies, hip shape was defined using geometric parameters measured on radiographs
14 such as femoral neck or centre-edge angle. An alternative approach, statistical shape modeling
15 (SSM), has been developed whereby principal component analysis is used to derive a set of
16 orthogonal hip shape modes (HSMs), which together provide a more complete description of hip
17 shape (7). Using this method, changes to the lateral curvature of the femoral head (7), and larger
18 femoral head relative to femoral shaft (8) have been reported to be associated with more rapid
19 progression of radiographic hip OA (RHOA) and, interestingly, with prevalent knee OA(9).
20 However, these studies were based on SSM of the femoral head alone, additional information is
21 provided by models which also include the acetabulum(10). For example, in a recent study by
22 Agricola et al using a combined femoral head and acetabulum SSM, a retroverted acetabulum
23 (defined as the posterior acetabular wall located medially with respect to the centre of the
24 femoral head) was found to be predictive of RHOA (11).

25

1 A limitation of the above approaches towards studying hip shape is their reliance on use of
2 radiographs. Whereas sample sizes based on radiographic collections are large enough for
3 conventional epidemiological studies, they provide limited power for genetic studies. Lindner et
4 al examined genetic influences on hip shape in 929 cases of unilateral RHOA, observing
5 associations between three loci and hip shape following a look up of 41 candidates (12).
6 However, considerably larger samples, including unaffected individuals, are required to perform
7 genome wide association studies (GWAS) intended to identify novel genetic loci. For example,
8 in the osteoporosis field, the largest GWAS study to date identified 56 loci associated with bone
9 mineral density (BMD) of which 32 were novel, based on DXA scans from over 90,000
10 individuals from population based cohorts (13). Widely available hip DXA scans may also prove
11 useful in evaluating relationships between hip shape and hip OA. For example, Waarsing et al
12 applied a statistical model combining shape and density from hip DXA scans in 218 patients
13 with hip OA, following which several modes were found to be associated with features of RHOA
14 (14). However, to what extent pure shape measures derived from hip DXA scans are also related
15 to RHOA, and whether similar relationships are observed in population-based cohorts, is
16 currently unclear.

17 To establish whether DXA-derived hip shape represents a useful phenotype for future GWAS
18 studies intended to identify novel genetic risk factors for hip OA, in the present study, we aimed
19 to examine whether hip shape derived from a SSM applied to hip DXA scans is associated with
20 RHOA in the Osteoporotic Fractures in Men (MrOS) Study; in this population-based cohort, hip
21 radiographs were performed a mean of 4.6 years following baseline DXA scans. Given the lack
22 of concordance between radiographic findings and symptoms in hip OA (15), we also aimed to
23 examine to what extent hip shape shows equivalent associations with hip pain, ascertained at the
24 same time as hip radiographs using a combination of questionnaires and examination.

1 **Methods**

2 *Study participants*

3 The MrOS cohort, within which this cross-sectional study is based, is a prospective study of
4 5,994 men recruited between 2000-2002 at six centers around the United States (Birmingham,
5 Alabama; Minneapolis, Minnesota; Palo Alto, California; the Monongahela Valley near
6 Pittsburgh, Pennsylvania; Portland, Oregon; and San Diego, California). To be eligible, men had
7 to be ≥ 65 years old, ambulatory, and without bilateral hip replacements. A full description of the
8 MrOS cohort has been previously published (16, 17). We used hip shape data derived from DXA
9 scans performed at the baseline visit, as part of a separate study examining genetic influences on
10 this phenotype. Pelvic X-rays for assessing RHOA, and hip examination and symptoms
11 questionnaire, were obtained as part of a second visit conducted from March 2005 to May 2006,
12 on average 4.6 years later.

13

14 *Demographic characteristics*

15 All demographic information is taken from visit one. The participant's age was taken as the age
16 in years at their last birthday. A Harpenden stadiometer (Holtain Ltd, Crynch, Wales) measured
17 standing height in centimeters, which was based on an average of two readings, if these differed
18 by ≥ 4 mm, two further readings were taken. Weight was measured to the nearest 0.1 kilograms
19 using a standard balance-beam scale or digital scales using standard protocols. Race was a self-
20 identified criterion with the participants asked to select one of the following: white, African
21 American, Asian, native Hawaiian or other Pacific Islander, American Indian or Alaskan native,
22 multi-racial and unknown.

23

1 *DXA protocol*

2 Right hip DXA imaging was performed at the baseline visit unless they had a right hip
3 replacement in which case a left hip scan was performed. A QDR 4500 Hologic machine
4 (Waltham, MA) was used at all six sites. There was a standardized protocol for positioning
5 participants and all DXA technicians were certified centrally (18).

6

7 *Statistical shape modelling*

8 Hip DXA scans were uploaded to SHAPE software (University of Aberdeen). A 58-point model
9 was used that automatically placed points around anatomical landmarks of the upper femur and
10 adjacent acetabulum; all images were reviewed and, where necessary, points were manually re-
11 positioned by a trained operator to ensure they were positioned on the bone edge (Figure 1).
12 Before marking up MrOS scans, a training set of 100 images was used to ensure accurate point
13 placement. Median point-to-point difference (ie distance between a given point placed by the
14 operator and the average point after combining placements by all operators) was derived for each
15 operator, a score of ≤ 3 pixels denoting acceptable accuracy. Firstly, Procrustes analysis was
16 performed to transform the points without deformation by scaling, rotation and translation so that
17 they are aligned as closely as possible, this is followed by Principal Component Analysis (PCA).
18 SHAPE is based on the algorithm first validated by Cootes et al when measuring the shape of
19 resistors, heart chambers and hands and more recently validated by Linder et al against manually
20 derived geometric measures from hip radiographs (19, 20). SHAPE through SSM produces
21 linearly independent variations in hip shape (hip shape modes (HSM))(21, 22). Each mode was
22 normalized to zero mean and unit standard deviation for the whole cohort so that each image
23 (and therefore participant) is assigned a set of mode scores in units of standard deviations (SD)
24 describing how far they lie from the mean. Images producing HSM scores above or below 4SDs

1 were manually checked by two operators, and point placement corrected where necessary. Mode
2 shapes were subsequently assigned to cam or pincer-type deformities based on consensus visual
3 interpretation.

5 ***Radiographic hip OA***

6 At visit two, standing pelvic radiographs were performed using a standardized protocol. Each
7 radiograph was read by a primary reader and scored, using a previously published atlas (23), for
8 concentric, medial or lateral joint space narrowing (JSN) (0-4), osteophyte formation at the
9 inferior and superior femur and acetabulum (0-3), bone cysts (0-3), subchondral sclerosis (0-3),
10 and femoral head deformity (0-3) (18). In addition, binary measures were created for the
11 presence of osteophytes, JSN or subchondral sclerosis, based on mild (grade ≥ 1) used for
12 primary analyses, moderate (grade ≥ 2) or severe (grade ≥ 3) cut-offs. Radiographs with definite
13 osteophytes or JSN were then examined by a second reader to reach a consensus score. Croft
14 scores, based on an aggregate of these scores, were subsequently generated (24), with a score ≥ 2
15 (requiring the presence of osteophytes or JSN) taken as the presence of moderate RHOA which
16 was used in primary analyses, and a score ≥ 3 denoting severe RHOA (18).

18 ***Hip pain***

19 All participants who attended visit two were asked to undergo a hip examination. The
20 participant's right hip was internally rotated and patient-reported pain was documented
21 generating a binary outcome. Participants completed a questionnaire concerning right hip pain on
22 walking in the last thirty days (scored 0-4), which was converted to a binary measure i.e.
23 presence or absence of right hip pain on walking in the last thirty days. Finally, all patients had a

1 standardized Western Ontario and McMaster Universities Arthritis Index (WOMAC) score
2 calculated out of 20. The WOMAC score, which has been validated as a measure of hip OA (25),
3 encompasses pain, stiffness and function to give an overall score of disease, 0 being no limitation
4 and 20 being severe limitation,

5

6 *Statistical analysis*

7 To limit multiple testing, we restricted our analyses to the ten HSMs explaining the greatest
8 proportion of variance in hip shape. Demographic statistics were summarized as mean (SD) for
9 continuous variables and counts (percentages) for categorical variables. Logistic regression was
10 used to analyse associations between each of these HSMs as separate predictors, modelled as
11 continuous variables, and binary OA outcomes; ordinal logistic regression was used to examine
12 relationships with WOMAC pain score outcomes, results are given as an odds ratio (OR).
13 Sensitivity analyses were also performed where we compared the results after applying different
14 Croft score definitions for OA, and different cut-offs for defining osteophytes. In the adjusted
15 regression models we adjusted for age, height, weight and race as *a priori* confounders, as
16 recorded at visit one. In setting P values for the strength of evidence against the null hypothesis,
17 we considered our top ten HSMs as independent exposures, and a global Croft score of ≥ 2
18 (indicating at least moderate OA) as our primary outcome, based on our fully adjusted model,
19 giving a Bonferroni-corrected P value of 0.005. All statistical analysis used Stata release 14
20 statistical software (StataCorp, College Station, TX, USA).

21

22

1 **Results**

2 *Population Characteristics*

3 Of the 5994 MrOS participants attending visit one, right DXA scans were available in 5862
4 (97.8%), having excluded those with incomplete data (N=86), previous joint replacement (N=45)
5 or poor image quality (N=1), from which hip shape was generated. At this baseline visit,
6 participants were a mean of 72.8 years of age, 83.6 kg in weight, and 174.4 cm in height, giving
7 mean BMI of 27.5 kg/m². At visit 2 (a mean of 4.6 years later), right hip radiographs were read
8 for RHOA, which were available for 4100 (69.9%) of these participants, who formed the basis of
9 the present study, of whom 90.7% were white, 3.3% Asian, 3.2% African American and 2.8%
10 multiracial/unknown/other.

11 At visit 2, 7.1% had evidence of RHOA, based on Croft score ≥ 2 (Table 1). Lateral acetabular
12 osteophytes were the most common radiographic feature of hip OA, with any osteophyte at this
13 site present in 19.2% of participants. Furthermore, at visit 2, 11.4% had hip pain on examination,
14 and 20.2% reported hip pain on walking.

15

16 *Hip shape modes*

17 The first ten HSMs in our cohort explained 81.4% of the total variance in hip shape. Five HSMs
18 were found to be associated with RHOA (see below), which together explained 48.3% of the
19 total variance in hip shape. All five HSMs associated with RHOA showed features of FAI on
20 visual inspection, either in the form of pincer- or cam-type deformities (Figures 2 & 3), whereas
21 the remaining HSMs were unrelated to these deformities. No HSM was related to both
22 deformities, implying these represent statistically independent contributions to hip shape. HSM
23 1, which accounted for 22.3% of total variance in hip shape, was positively associated with

1 pincer-type deformity (Figure 2). HSM 8, which accounted for 2.8% of total variance in hip
2 shape, was negatively associated with pincer-type deformity. HSM 3 and HSM 4, which
3 explained 12.1% and 9.2% of total variation in hip shape respectively, were negatively
4 associated with cam-type deformity (Figure 3). HSM 10, which explained 1.9% of total variation
5 in hip shape, was positively associated with cam-type deformity.

6 These modes also reflected other shape differences. HSM 1 was associated with a larger femoral
7 head, larger lesser and greater trochanters, wider femoral neck width, and narrower supero-
8 medial joint space; HSM 3 was related to a smaller lesser trochanter and narrower supero-medial
9 joint space; HSM 4 was associated with altered neck shaft angle leading to medial displacement
10 of the femoral head; and HSM 8 was related to a wider supero-lateral joint space. In contrast, the
11 HSMs not associated with measures of hip OA were unrelated to pincer- or cam-type
12 deformities; HSM 2 featured a smaller femoral head with a steeper femoral neck angle and larger
13 lesser trochanter, HSM 5 a smaller lesser trochanter, HSM 6 a deeper superior curvature to the
14 femoral neck and larger lesser trochanter, HSM 7 a smaller lesser trochanter and HSM 9 a
15 smaller femoral head.

16

17 *Hip shape modes 1 and 8 (pincer-type deformities) versus radiographic hip osteoarthritis*

18 In unadjusted analyses, HSM 1 was positively associated with the presence of RHOA, defined as
19 Croft score ≥ 2 [OR 1.23 (1.09, 1.39)], whereas HSM 8 was negatively associated [OR 0.79
20 (0.70, 0.89)] (Table 2). Results were unaffected by adjustment for age, weight, height and race.

21 In terms of specific radiographic components, in adjusted analyses, HSM 1 was positively
22 associated with the presence of acetabular [OR 1.13 (1.04, 1.22)] and inferior femoral [OR 1.22
23 (1.07, 1.38)] osteophytes (Table 3), and with medial JSN [OR 1.55 (1.40, 1.71)] and subchondral
24 sclerosis [OR 1.23 (1.09, 1.39)] (Table 4). Conversely, HSM 8 was inversely associated with

1 osteophytes at all four locations (OR 0.78 to 0.89) (Table 4), and with lateral JSN [OR 0.71
2 (0.62, 0.82)] and subchondral sclerosis [OR 0.79 (0.69, 0.89)].

3

4 ***Hip shape modes 3, 4 and 10 (cam-type deformities) versus radiographic hip osteoarthritis***

5 In unadjusted analyses, HSM 3 and HSM 4 were inversely associated with prevalent RHOA [OR
6 0.73 (0.65, 0.83) and 0.82 (0.73, 0.93) respectively], whereas HSM10 was positively related [OR
7 1.21 (1.07, 1.37)] (Table 2). Equivalent results were seen in analyses adjusted for age, weight,
8 height and race. In terms of specific radiographic components, in adjusted analyses HSM 3 was
9 inversely related to the presence of osteophytes at all sites (OR 0.76 to 0.89) (Table 3), and to
10 lateral JSN [0.73 (0.63, 0.84)] and subchondral sclerosis [OR 0.76 (0.67, 0.85)], whereas there
11 was a positive association with medial JSN [OR 1.32 (1.19, 1.46)] (Table 4). HSM 4 was
12 inversely related to the presence of inferior acetabular osteophytes [OR 0.83 (0.75, 0.92)], but
13 positively related to medial JSN [OR 1.32 (1.20, 1.46)]. HSM 10 was positively associated with
14 inferior femoral osteophytes [OR 1.22 (1.07, 1.39)] and subchondral sclerosis [OR 1.21 (1.07,
15 1.38)]. Equivalent observations were seen in unadjusted analyses (data not shown).

16

17 ***Association of hip shape with hip pain***

18 In adjusted analyses, HSM 3 was inversely associated with hip pain on internal rotation [OR 0.84
19 (0.76, 0.92)] and on walking [OR 0.88 (0.81, 0.95)], and with WOMAC pain score [OR 0.87
20 (0.80, 0.93)]. Similar results were seen in unadjusted analyses (data not shown). There was weak
21 evidence that HSM 4 was inversely associated with hip pain on examination and on walking and
22 with WOMAC score, and that HSM 8 was positively related to these parameters (all $P < 0.02$);
23 however, for all these p values were > 0.005 .

1 ***Sensitivity analyses***

2 Similar point estimates were observed for associations between HSMs and RHOA using a
3 definition of Croft score ≥ 3 as opposed to ≥ 2 (Table 2). Equivalent results were also obtained
4 for associations between hip shape and moderate or severe osteophytes (*i.e.* grade ≥ 2), compared
5 to those seen for grade ≥ 1 osteophytes as presented in the main results (Table 3).

6

ACCEPTED MANUSCRIPT

1 Discussion

2 We examined associations between hip shape, as assessed by SSM performed on hip DXA scans,
3 and prevalent radiographic hip OA ascertained approximately five years later, in a large
4 population based cohort of older men. We found that five out of the top ten hip shape modes
5 were associated with prevalent RHOA, and one mode was also associated with hip pain. Taken
6 together, these findings suggest that SSM applied to hip DXA scans can be successfully used to
7 identify shape changes associated with hip OA, particularly radiographic features. Given the
8 substantial number of large population based cohorts with available hip DXA scans, this finding
9 opens up the possibility of identifying novel genetic risk factors for hip OA, based on GWAS
10 studies of DXA-derived hip shape.

11 All five hip shape modes associated with RHOA showed features of FAI, reflecting either cam-
12 or pincer-type deformities. Given the cross-sectional nature of this analysis, it was not possible to
13 distinguish shape changes resulting from hip OA, from those causing it. That said, our finding
14 that three hip shape modes, indicative of cam-type deformity, are related to RHOA is consistent
15 with previous studies suggesting that cam-type deformity is a risk factor for RHOA, based on
16 SSM (26), and measured geometric parameters (27, 28). As well as being related to global
17 RHOA as reflected by Croft score, HSM 3, HSM 4, and HSM 10 showed equivalent
18 relationships with osteophytes at different sites, and in the case of HSM 3 with lateral JSN and
19 subchondral sclerosis. HSM 3 also showed the strongest association with hip pain. However, the
20 associations between hip shape and hip pain were generally weaker than that for RHOA. This
21 lack of concordance between radiographic and clinical features of hip OA is well recognized
22 (15), and was supported by further analyses in which we examined associations between RHOA
23 as defined by Croft score ≥ 2 and clinical features. Whereas RHOA was positively associated

1 with pain on examination and on walking, these associations were relatively modest (RR 1.67
2 and 1.51 respectively).

3 Our observation that two HSMs reflecting pincer-type deformity were positively associated with
4 RHOA is also consistent with the view that pincer-type deformity contributes to FAI, which is in
5 turn thought to be an important cause of hip OA (5). That said, there is little evidence that pincer-
6 type deformity is associated with RHOA in the general population. Indeed, in a recent study of
7 720 individuals from the CHECK study, pincer-type deformity, as measured on radiographs
8 based on the centre-edge angle, was found to be protective against incident OA (2). One possible
9 explanation for these apparently discrepant findings is that the relationship between pincer-type
10 deformity and RHOA depends upon gender, since our present findings derived from the all-male
11 MrOS cohort, whereas CHECK was 79% female.

12 Whilst the five HSMs associated with RHOA could be divided into those reflecting cam- and
13 pincer-type deformities, these appearances may have arisen as a consequence of other OA related
14 phenotypes. For example, the image resolution of DXA scans used in this study was too low to
15 clearly visualize osteophytes, and so superior femoral osteophytes and lateral acetabular
16 osteophytes may have been included inadvertently, leading to the impression of cam-and pincer-
17 type deformities respectively. Moreover, since we were only able to include the superior
18 acetabulum in our SSM, we were unable to evaluate medial JSN and to exclude medial
19 displacement of the femoral head as a cause of acetabular overhang, as opposed to pincer-type
20 deformity. Our observation that HSM 1, which was positively related to pincer-type deformity,
21 was also positively related to medial JSN on subsequent radiographs, is consistent with this
22 alternative explanation.

23 As well as contributing to cam- and pincer-type deformities, hip shape modes may have reflected
24 the presence of OA in other ways. For example, HSM 1 and HSM 3 were suggestive of greater

1 supero-medial JSN, and HSM 8 lesser supero-lateral JSN. In addition, alteration in the size of the
2 lesser trochanter associated with HSM 3 may reflect variation in the extent of internal rotation of
3 the hip during image acquisition, which may in turn reflect underlying hip OA given the latter is
4 associated with limited internal rotation. Hip shape modes were also related to differences which
5 may reflect other risk factors for developing OA apart from FAI. For example, HSM 1 was
6 related to size of the femoral head and greater trochanter, and femoral neck width, which have
7 recently been reported to be associated with prevalent radiographic knee OA (9). That said, HSM
8 2 and HSM 9, which were also related to femoral head size but showed no relation to pincer-or
9 cam-type deformities, were unrelated to RHOA or hip pain.

10 *Strengths and limitations*

11 This study represents the first report of associations between DXA-derived hip shape and RHOA
12 in a population based sample. The large size of the sample represents a further strength. The fact
13 that this is a male cohort may have further increased power in light of previous findings
14 suggesting the relationships between hip shape and RHOA are stronger in males than in females
15 (29), though to what extent our findings are applicable to females requires further study. Our
16 study also highlights the benefit of using large DXA cohorts for hip shape research, though given
17 the greater resolution of radiographs, the latter are more suitable in smaller studies, and in
18 clinical practice. One limitation of this study was our lack of baseline radiographs. Therefore, the
19 associations which we observed between HSMs, as assessed on baseline DXA scans, and RHOA
20 based on radiographs collected five years later, could have reflected relationships with prevalent
21 as opposed to incident OA. This distinction is important, since in examining associations with
22 prevalent OA, it is difficult to infer causality, and the shape changes we observed could have
23 been a result of, rather than a risk factor for, hip OA. A further limitation is the relatively low
24 image resolution of the DXA scanner used in MrOS, making it difficult to determine to what

1 extent associations between DXA-derived hip shape and RHOA reflected characteristics of
2 established OA such as osteophytes, as opposed to shape changes representing possible OA risk
3 factors such as those related to FAI. Newer DXA devices provide sufficient resolution for
4 identifying osteophytes on hip DXA scans (30). In addition, shape results could conceivably be
5 affected by the degree of hip rotation; although the lower leg is strapped into a fixed position
6 during scanning, the degree of hip rotation achieved might be affected by anatomical features
7 such as pelvic size and shape, and associated hip disease. Another limitation, is that our HSMs
8 cannot be directly applied to other cohorts since SSM using PCA is specific to the images used
9 to make the model. Finally, SSM is not designed specifically to evaluate FAI and based on our
10 findings more analysis, using methods specific to FAI such as alpha-angle, should be done to
11 replicate these findings.

12 ***Conclusions***

13 Having applied a SSM of the femoral head and superior acetabulum to hip DXA scans from the
14 MrOS cohort, we found that five out of the top ten hip shape modes were associated with
15 RHOA, of which one mode was also related to hip pain. That these modes were associated with
16 either cam- or pincer-type deformities is consistent with previous studies implicating FAI in the
17 pathogenesis of hip OA. Furthermore, the observation that DXA-derived hip shape is related to
18 prevalent hip OA suggests this may represent a useful phenotype for future GWAS studies
19 intended to identify novel genetic risk factors for hip OA.

20

1 **Acknowledgements**

2 BF conducted this research whilst on a clinical research primer fellowship awarded by the
3 Elizabeth Blackwell Institute, University of Bristol, UK. This study was funded by Arthritis
4 Research UK project grant ref 20244. CG is funded by Arthritis Research UK grant ref 20000.
5 The Osteoporotic Fractures in Men (MrOS) Study is supported by National Institutes of Health
6 funding. The following institutes provide support: the National Institute on Aging (NIA), the
7 National Institute of Arthritis and Musculoskeletal and Skin Diseases (NIAMS), the National
8 Center for Advancing Translational Sciences (NCATS), and NIH Roadmap for Medical
9 Research under the following grant numbers: R01 AR052000, K24 AR048841, U01 AG027810,
10 U01 AG042124, U01 AG042139, U01 AG042140, U01 AG042143, U01 AG042145, U01
11 AG042168, U01 AR066160, and UL1 TR000128.

12

1 Author Contributions

2 BF, CG, RA, EO and JT conceptualized the study. BF, DB, JG, RB, JL, MN, NL and EO
3 collected the data. BF, DB, CG, EO and JT developed the analysis plan and analysed the data.
4 BF, RA, NL, EO, JT obtained funding. All authors contributed to the interpretation of the results,
5 wrote the manuscript and have approved the final version of the manuscript. BF had full access
6 to all the data and takes responsibility for its integrity and accuracy.

- 1 **Conflict of Interest**
- 2 We have none to declare.

ACCEPTED MANUSCRIPT

1 **References:**

- 2 1. Verbrugge LM, Patrick DL. Seven chronic conditions: their impact on US adults' activity
3 levels and use of medical services. *American Journal of Public Health*. 1995;85(2):173-82.
- 4 2. Agricola R, Heijboer MP, Roze RH, Reijman M, Bierma-Zeinstra SM, Verhaar JA, et al.
5 Pincer deformity does not lead to osteoarthritis of the hip whereas acetabular dysplasia does:
6 acetabular coverage and development of osteoarthritis in a nationwide prospective cohort study
7 (CHECK). *Osteoarthritis Cartilage*. 2013;21(10):1514-21.
- 8 3. Baker-LePain JC, Lane NE. Relationship between joint shape and the development of
9 osteoarthritis. *Curr Opin Rheumatol*. 2010;22(5):538-43.
- 10 4. Ganz R, Parvizi J, Beck M, Leunig M, Nötzli H, Siebenrock KA. Femoroacetabular
11 Impingement: A Cause for Osteoarthritis of the Hip. *Clinical Orthopaedics and Related
12 Research*. 2003;417:112-20.
- 13 5. Beck M, Kalhor M, Leunig M, Ganz R. Hip morphology influences the pattern of
14 damage to the acetabular cartilage: femoroacetabular impingement as a cause of early
15 osteoarthritis of the hip. *J Bone Joint Surg Br*. 2005;87(7):1012-8.
- 16 6. Murray RO. The aetiology of primary osteoarthritis of the hip. *Br J Radiol*.
17 1965;38(455):810-24.
- 18 7. Gregory JS, Waarsing JH, Day J, Pols HA, Reijman M, Weinans H, et al. Early
19 identification of radiographic osteoarthritis of the hip using an active shape model to quantify
20 changes in bone morphometric features: Can hip shape tell us anything about the progression of
21 osteoarthritis? *Arthritis & Rheumatism*. 2007;56(11):3634-43.
- 22 8. Lynch JA, Parimi N, Chaganti RK, Nevitt MC, Lane NE. The association of proximal
23 femoral shape and incident radiographic hip OA in elderly women. *Osteoarthritis and Cartilage*.
24 2009;17(10):1313-8.
- 25 9. Nelson AE, Golightly YM, Renner JB, Schwartz TA, Liu F, Lynch JA, et al. Variations
26 in Hip Shape Are Associated with Radiographic Knee Osteoarthritis: Cross-sectional and
27 Longitudinal Analyses of the Johnston County Osteoarthritis Project. *J Rheumatol*.
28 2016;43(2):405-10.
- 29 10. Barr RJ, Gregory JS, Reid DM, Aspden RM, Yoshida K, Hosie G, et al. Predicting OA
30 progression to total hip replacement: can we do better than risk factors alone using active shape
31 modelling as an imaging biomarker? *Rheumatology (Oxford)*. 2012;51(3):562-70.
- 32 11. Agricola R, Reijman M, Bierma-Zeinstra SMA, Verhaar JAN, Weinans H, Waarsing JH.
33 Total hip replacement but not clinical osteoarthritis can be predicted by the shape of the hip: a
34 prospective cohort study (CHECK). *Osteoarthritis and Cartilage*. 2013;21(4):559-64.
- 35 12. Lindner C, Thiagarajah S, Wilkinson JM, Panoutsopoulou K, Day-Williams AG, arc OC,
36 et al. Investigation of association between hip osteoarthritis susceptibility loci and radiographic
37 proximal femur shape. *Arthritis Rheumatol*. 2015;67(8):2076-84.
- 38 13. Estrada K, Styrkarsdottir U, Evangelou E. Genome-wide meta-analysis identifies 56 bone
39 mineral density loci and reveals 14 loci associated with risk of fracture. *Nature Genetics*.
40 2012;15;44(5):491-501.
- 41 14. Waarsing JH, Rozendaal RM, Verhaar JA, Bierma-Zeinstra SM, Weinans H. A statistical
42 model of shape and density of the proximal femur in relation to radiological and clinical OA of
43 the hip. *Osteoarthritis Cartilage*. 2010;18(6):787-94.
- 44 15. Kinds MB, Welsing PM, Vignon EP, Bijlsma JW, Viergever MA, Marijnissen AC, et al.
45 A systematic review of the association between radiographic and clinical osteoarthritis of hip and
46 knee. *Osteoarthritis Cartilage*. 2011;19(7):768-78.

- 1 16. Blank JB, Cawthon PM, Carrion-Petersen ML, Harper L, Johnson JP, Mitson E, et al.
2 Overview of recruitment for the osteoporotic fractures in men study (MrOS). *Contemp Clin*
3 *Trials*. 2005;26(5):557-68.
- 4 17. Orwoll E, Blank JB, Barrett-Connor E, Cauley J, Cummings S, Ensrud K, et al. Design
5 and baseline characteristics of the osteoporotic fractures in men (MrOS) study, a
6 large observational study of the determinants of fracture in older men. *Contemporary Clinical*
7 *Trials*. 2005;26(5):569-85.
- 8 18. Chaganti RK, Parimi N, Lang T, Orwoll E, Stefanick ML, Nevitt M, et al. Bone Mineral
9 Density and Prevalent Osteoarthritis of the Hip in Older Men for the Osteoporotic Fractures in
10 Men (MrOS) Study Group. *Osteoporosis International*. 2010;21(8):1307-16.
- 11 19. Cootes TF, Taylor CJ, Cooper DH, Graham J. Active shape models - Their training and
12 application. *Computer vision and image understanding*. 1995;61(1):38-59.
- 13 20. Lindner C, Thiagarajah S, Wilkinson JM, arc OC, Wallis GA, Cootes TF. Development
14 of a fully automatic shape model matching (FASMM) system to derive statistical shape models
15 from radiographs: application to the accurate capture and global representation of proximal
16 femur shape. *Osteoarthritis Cartilage*. 2013;21(10):1537-44.
- 17 21. Gregory JS, Aspden RM. Femoral geometry as a risk factor for osteoporotic hip fracture
18 in men and women. *Med Eng Phys*. 2008;30(10):1275-86.
- 19 22. Ahedi HG, Aspden RM, Blizzard LC, Saunders FR, Cicuttini FM, Aitken DA, et al. Hip
20 shape as a predictor of osteoarthritis progression in a prospective population cohort. *Arthritis*
21 *Care Res (Hoboken)*. 2016.
- 22 23. Lane NE, Nevitt MC, Genant HK, Hochberg MC. Reliability of new indices of
23 radiographic osteoarthritis of the hand and hip and lumbar disc degeneration. *J Rheumatol*.
24 1993;20(11):1911-8.
- 25 24. Croft P, Cooper C, Wickham C, Coggon D. Defining osteoarthritis of the hip for
26 epidemiologic studies. *American Journal of Epidemiology*. 1990;132(3):514-22.
- 27 25. Bellamy N, Buchanan WW, Goldsmith CH, Campbell J, Stitt LW. Validation study of
28 WOMAC: a health status instrument for measuring clinically important patient relevant
29 outcomes to antirheumatic drug therapy in patients with osteoarthritis of the hip or knee. *J*
30 *Rheumatol*. 1988;15(12):1833-40.
- 31 26. Waarsing JH, Rozendaal RM, Verhaar JAN, Bierma-Zeinstra SMA, Weinans H. A
32 statistical model of shape and density of the proximal femur in relation to radiological and
33 clinical OA of the hip. *Osteoarthritis and Cartilage*. 2010;18(6):787-94.
- 34 27. Agricola R, Heijboer MP, Bierma-Zeinstra SMA, Verhaar JAN, Weinans H, Waarsing
35 JH. Cam impingement causes osteoarthritis of the hip: a nationwide prospective cohort study
36 (CHECK). *Annals of the Rheumatic Diseases*. 2013;72(6):918-23.
- 37 28. Doherty M, Courtney P, Doherty S, Jenkins W, Maciewicz RA, Muir K, et al.
38 Nonspherical femoral head shape (pistol grip deformity), neck shaft angle, and risk of hip
39 osteoarthritis: a case-control study. *Arthritis Rheum*. 2008;58(10):3172-82.
- 40 29. Nelson AE, Liu F, Lynch JA, Renner JB, Schwartz TA, Lane NE, et al. Association of
41 Incident Symptomatic Hip Osteoarthritis With Differences in Hip Shape by Active Shape
42 Modeling: The Johnston County Osteoarthritis Project. *Arthritis Care & Research*.
43 2014;66(1):74-81.
- 44 30. Yoshida K, Barr RJ, Galea-Soler S, Aspden RM, Reid DM, Gregory JS. Reproducibility
45 and Diagnostic Accuracy of Kellgren-Lawrence Grading for Osteoarthritis Using Radiographs
46 and Dual-Energy X-ray Absorptiometry Images. *J Clin Densitom*. 2015;18(2):239-44.

1

2

ACCEPTED MANUSCRIPT

1 **Table 1** Prevalence of radiographic and hip OA and hip pain

	Prevalence n [%]
Radiographic OA	
Croft <2	3811 [93]
Croft ≥2	289 [7.1]
Croft ≥3	100 [2.4]
<i>Any osteophyte (i.e. score ≥ 1)</i>	
Lateral acetabular	788 [19.2]
Lateral femoral	401 [9.8]
Inferior acetabular	404 [9.9]
Inferior femoral	272 [6.6]
<i>Any joint space narrowing (i.e. score ≥ 1)</i>	
Lateral	207 [5.1]
Medial	446 [10.9]
Concentric	148 [3.6]
<i>Other bone lesions</i>	
Cysts	44 [1.1]
Any subchondral sclerosis(i.e. score ≥ 1)	278 [6.8]
Chondrocalcinosis	9 [0.02]
Joint deformity	35 [0.9]
Symptoms	
Hip pain on examination	451 [11.4]
Hip pain on walking	829 [20.2]
WOMAC	0.9 [2.3, 0, 20.0]

2

3 Prevalence based on 4100 individuals with right hip X-rays. Results are shown as prevalence
4 [%], apart from the Western Ontario and McMaster Universities Arthritis Index (WOMAC)
5 score which is presented as mean [SD, Min, Max]. N = 4,100 except for pain on examination (N
6 = 3,946), walking (N = 4,098) and WOMAC score (N = 4,076).

Table 2 Associations of hip shape modes with the presence of radiographic hip OA based on the Croft score

	Unadjusted Croft ≥ 2		Adjusted Croft ≥ 2		Unadjusted Croft ≥ 3		Adjusted Croft ≥ 3	
	OR [95% CI]	P	OR [95% CI]	P	OR [95% CI]	P	OR [95% CI]	P
HSM 1	1.23 [1.09, 1.39]	0.00072*	1.23 [1.09, 1.39]	0.00082*	1.08 [0.89, 1.32]	0.43	1.10 [0.9, 1.35]	0.35
HSM 2	1.04 [0.92, 1.17]	0.56	1.01 [0.89, 1.14]	0.89	0.95 [0.78, 1.16]	0.63	0.93 [0.76, 1.14]	0.51
HSM 3	0.73 [0.65, 0.83]	3.6×10^{-7} *	0.73 [0.65, 0.83]	4.0×10^{-7} *	0.60 [0.50, 0.73]	3.7×10^{-7} *	0.60 [0.50, 0.73]	3.5×10^{-7} *
HSM 4	0.82 [0.73, 0.93]	0.0014*	0.83 [0.73, 0.93]	0.0021*	0.67 [0.55, 0.83]	0.00014*	0.69 [0.56, 0.84]	0.00028*
HSM 5	1.02 [0.91, 1.16]	0.71	1.03 [0.91, 1.17]	0.62	1.02 [0.83, 1.24]	0.88	1.01 [0.82, 1.24]	0.94
HSM 6	0.92 [0.82, 1.03]	0.14	0.92 [0.82, 1.03]	0.16	0.87 [0.72, 1.05]	0.15	0.86 [0.71, 1.05]	0.14
HSM 7	0.95 [0.84, 1.07]	0.40	0.98 [0.87, 1.11]	0.79	0.90 [0.74, 1.1]	0.30	0.96 [0.79, 1.18]	0.72
HSM 8	0.79 [0.70, 0.89]	0.00016*	0.78 [0.69, 0.88]	7.4×10^{-5} *	0.64 [0.52, 0.79]	2.6×10^{-5} *	0.63 [0.51, 0.78]	1.4×10^{-5} *
HSM 9	0.95 [0.84, 1.07]	0.39	0.95 [0.84, 1.07]	0.41	0.93 [0.76, 1.14]	0.48	0.94 [0.77, 1.14]	0.52
HSM 10	1.21 [1.07, 1.37]	0.0020*	1.24 [1.1, 1.41]	0.00061*	1.29 [1.05, 1.59]	0.014	1.35 [1.1, 1.66]	0.0048*

Table shows results of logistic regression analysis between hip shape modes (HSMs) and Croft score in 4,100 individuals. Results show odds ratio of having a Croft score per standard deviation increase in hip shape mode [95% confidence intervals] and *P*-value. Adjusted = adjusted analysis for age, weight, height and race. **P*<0.005

ACCEPTED MANUSCRIPT

Table 3 Associations of hip shape modes with osteophytes at different sites

	Osteophyte Score	Lateral acetabulum		Lateral femoral		Inferior acetabulum		Inferior femoral	
		OR [95% CI]	P value	OR [95% CI]	P value	OR [95% CI]	P value	OR [95% CI]	P value
HSM1	≥ 1	1.13 [1.04, 1.22]	0.0031*	1.11 [1.00, 1.24]	0.047	1.13 [1.02, 1.26]	0.019	1.22 [1.07, 1.38]	0.0022*
	≥ 2	1.01 [0.90, 1.14]	0.81	1.06 [0.91, 1.24]	0.45	1.18 [1.01, 1.39]	0.044	1.41 [1.10, 1.80]	0.0068
HSM3	≥ 1	0.89 [0.82, 0.96]	0.0034*	0.78 [0.70, 0.87]	2.7×10^{-6} *	0.76 [0.69, 0.85]	2.9×10^{-7} *	0.80 [0.71, 0.90]	0.00035*
	≥ 2	0.79 [0.70, 0.89]	7.5×10^{-5} *	0.60 [0.52, 0.71]	1.8×10^{-10} *	0.73 [0.62, 0.86]	0.00017*	0.73 [0.57, 0.93]	0.011
HSM4	≥ 1	0.92 [0.85, 1.00]	0.041	0.86 [0.78, 0.96]	0.0058	0.83 [0.75, 0.92]	0.00048*	0.86 [0.76, 0.97]	0.016
	≥ 2	0.96 [0.85, 1.08]	0.48	0.83 [0.71, 0.98]	0.024	0.83 [0.70, 0.97]	0.023	0.70 [0.55, 0.90]	0.0058
HSM8	≥ 1	0.89 [0.82, 0.96]	0.0034*	0.81 [0.73, 0.90]	7.7×10^{-5} *	0.84 [0.75, 0.93]	0.0011*	0.78 [0.69, 0.89]	0.00014*
	≥ 2	0.89 [0.79, 1.00]	0.046	0.74 [0.63, 0.87]	0.00025*	0.84 [0.71, 0.99]	0.035	0.77 [0.60, 0.99]	0.044
HSM10	≥ 1	1.12 [1.03, 1.21]	0.0063	1.10 [0.99, 1.22]	0.082	1.12 [1.01, 1.25]	0.035	1.22 [1.07, 1.39]	0.0022*
	≥ 2	1.1 [0.98, 1.24]	0.11	1.17 [1.00, 1.37]	0.054	1.23 [1.04, 1.45]	0.017	1.40 [1.08, 1.82]	0.010

Table shows results of logistic regression analysis between hip shape modes (HSMs) and osteophytes, dependent on score ≥ 1 (any osteophyte) and ≥ 2 (moderate to severe osteophytes only), at different sites in 4,100 individuals. Results show odds ratio of having any osteophyte per standard deviation increase in hip shape mode [95% confidence intervals] and p value, adjusted for age, weight, height and race. *P<0.005

Table 4 Associations of hip shape modes with joint space narrowing and subchondral sclerosis

	Lateral JSN		Medial JSN		Concentric JSN		Subchondral sclerosis	
	OR [95% CI]	P value	OR [95% CI]	P value	OR [95% CI]	P value	OR [95% CI]	P value
HSM1	1.01 [0.87, 1.16]	0.91	1.55 [1.40, 1.71]	4.3×10^{-17} *	1.23 [1.04, 1.45]	0.013	1.23 [1.09, 1.39]	0.0011*
HSM3	0.73 [0.63, 0.84]	8.6×10^{-6} *	1.32 [1.19, 1.46]	9.2×10^{-8} *	0.98 [0.83, 1.15]	0.79	0.76 [0.67, 0.85]	6.8×10^{-6} *
HSM4	0.84 [0.73, 0.97]	0.020	1.32 [1.20, 1.46]	5.9×10^{-8} *	1.05 [0.89, 1.25]	0.54	0.84 [0.74, 0.95]	0.0067
HSM8	0.71 [0.62, 0.82]	4.3×10^{-6} *	0.87 [0.78, 0.96]	0.0057	0.87 [0.74, 1.03]	0.11	0.79 [0.69, 0.89]	0.00018*
HSM10	1.16 [1.01, 1.35]	0.039	1.11 [1.00, 1.23]	0.041	0.93 [0.79, 1.10]	0.39	1.21 [1.07, 1.38]	0.0025*

Table shows results of logistic regression analysis between hip shape modes (HSM) and joint space narrowing (JSN) and subchondral sclerosis in 4,100 individuals. Results show odds ratio of having any JSN or subchondral sclerosis per standard deviation increase in hip shape mode [95% confidence intervals] and p value, adjusted analysis for age, weight, height and race. *P<0.005

Figure Legends

Figure 1: An example DXA image

Figure 1

This is a DXA image taken from the MrOS cohort. The 58 points used for the SSM are marked on the image. Key points are marked in red and these represent anatomical reference points to ensure accurate marking. There are two key lateral acetabular points placed on the outer edge of the acetabulum and one key medial acetabular point placed at the end of the acetabular eyebrow. The other key points are located around the trochanters, the femoral head and the femoral neck.

Figure 2: Hip shape modes 1 and 8Figure 2

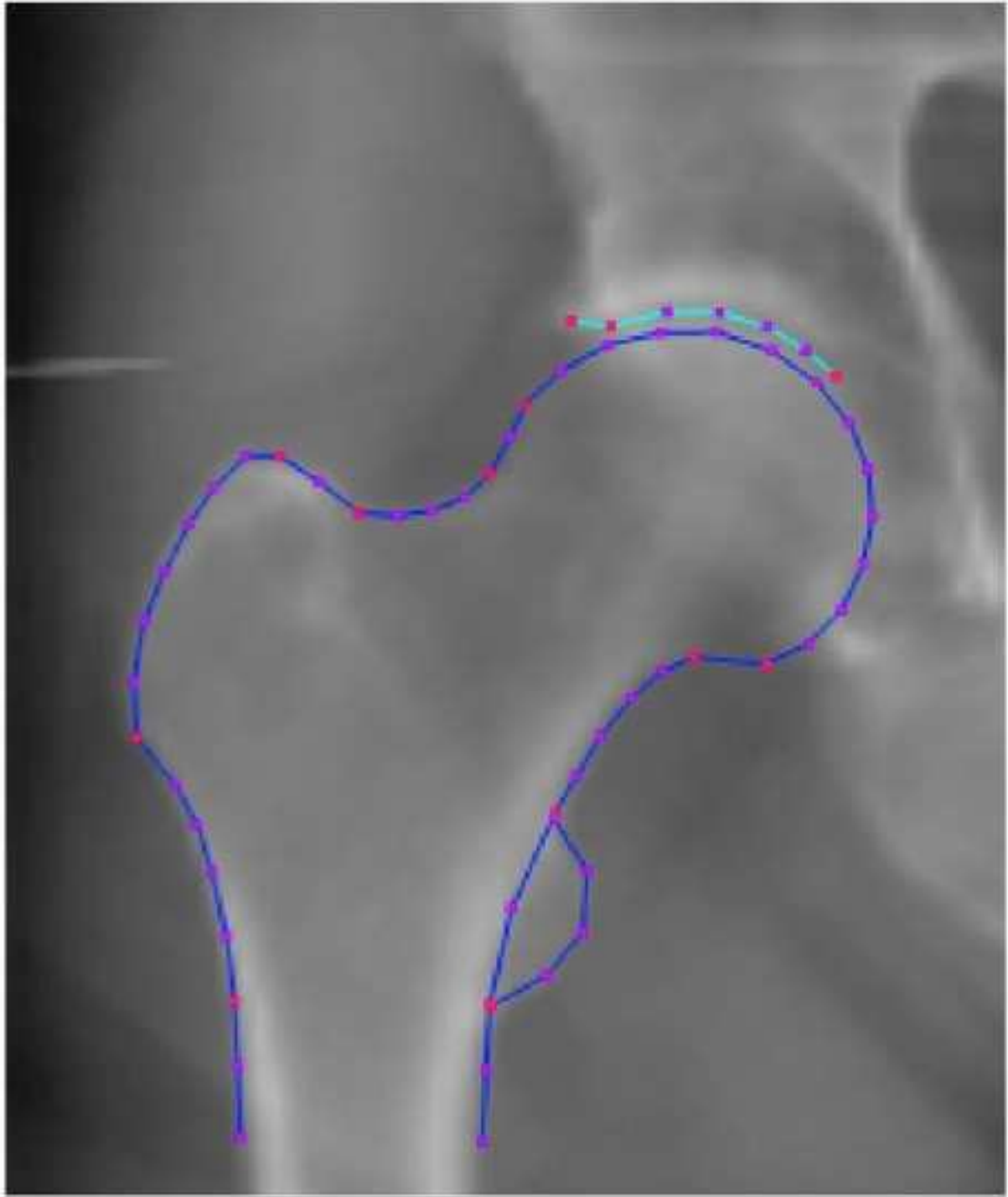
Pincer-type variations in hip shape demonstrated by hip shape mode 1 and hip shape mode 8. Hip shape mode 1 has a positive relationship with a pincer-type variation. Hip shape mode 8 has a negative relationship with a pincer-type variation. Dashed line = +2 SDs, solid line = - 2SDs

Figure 3: Hip shape modes 3, 4 and 10

Figure 3

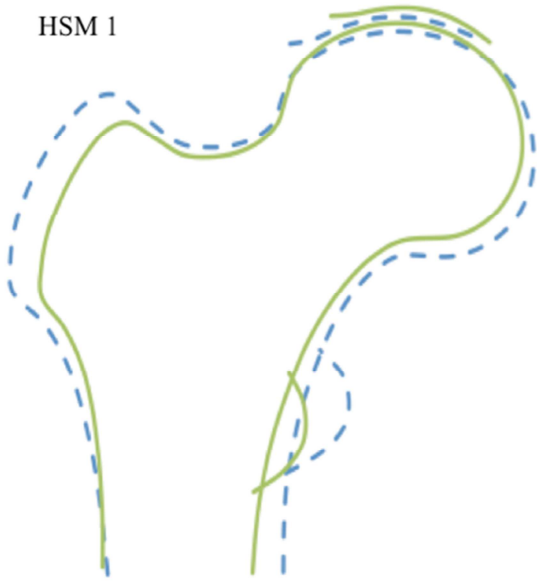
Cam-type variation in hip shape demonstrated by hip shape modes 3, 4 and 10. Hip shape modes 3 and 4 have a negative relationship with a cam-type variation. Hip shape mode 10 has a positive relationship with a cam-type variation. Dashed line = +2 SDs, solid line = - 2SDs.

ACCEPTED MANUSCRIPT

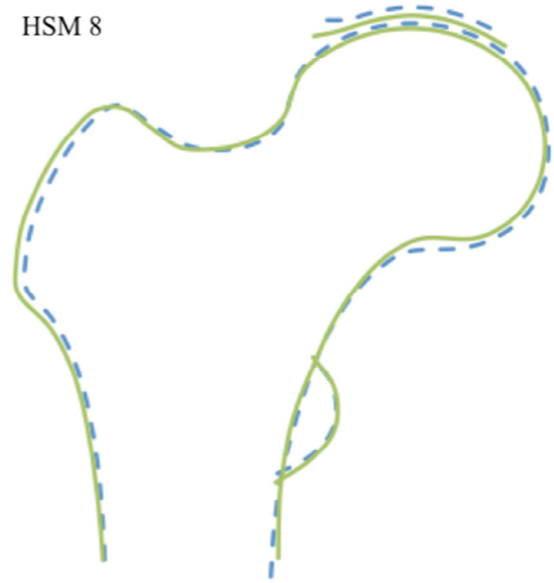


AC

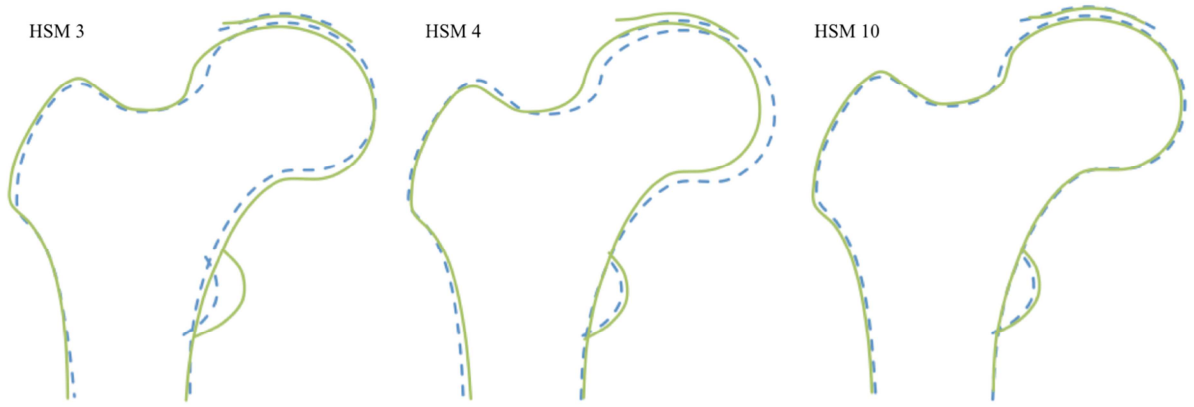
HSM 1



HSM 8



ACCEPTED MANUSCRIPT



ACCEPTED MANUSCRIPT