

# Clinical Spectrum of LIG4 Deficiency Is Broadened with Severe Dysmaturity, Primordial Dwarfism, and Neurological Abnormalities

Hanna IJspeert,<sup>1,2</sup> Adilia Warris,<sup>3</sup> Michiel van der Flier,<sup>3</sup> Ismail Reisli,<sup>4</sup> Sevgi Keles,<sup>4</sup> Sandra Chishimba,<sup>1</sup> Jacques J.M. van Dongen,<sup>1</sup> Dik C. van Gent,<sup>5</sup> and Mirjam van der Burg<sup>1\*</sup>

<sup>1</sup>Department of Immunology, Erasmus MC, University Medical Center Rotterdam, Rotterdam, The Netherlands; <sup>2</sup>Department of Pediatrics, Erasmus MC, Rotterdam, The Netherlands; <sup>3</sup>Department of Pediatrics and the Nijmegen Institute for Infection, Inflammation and Immunity, Radboud University Nijmegen Medical Center, Nijmegen, The Netherlands; <sup>4</sup>Department of Pediatric Immunology and Allergy, Necmettin Erbakan University Meram Medical Faculty, Konya, Turkey; <sup>5</sup>Department of Genetics, Erasmus MC, University Medical Center Rotterdam, Rotterdam, The Netherlands

Communicated by Haig H. Kazazian

Received 15 February 2013; accepted revised manuscript 20 August 2013.

Published online 11 September 2013 in Wiley Online Library (www.wiley.com/humanmutation). DOI: 10.1002/humu.22436

**ABSTRACT:** DNA double-strand break repair via non-homologous end joining (NHEJ) is involved in recombination of immunoglobulin and T-cell receptor genes. Mutations in NHEJ components result in syndromes that are characterized by microcephaly and immunodeficiency. We present a patient with lymphopenia, extreme radiosensitivity, severe dysmaturity, corpus callosum agenesis, polysyndactyly, dysmorphic appearance, and erythema, which are suggestive of a new type of NHEJ deficiency. We identified two heterozygous mutations in *LIG4*. The p.S205LfsX29 mutation results in lack of the nuclear localization signal and appears to be a null mutation. The second mutation p.K635RfsX10 lacks the C-terminal region responsible for XRCC4 binding and *LIG4* stability and activity, and therefore this mutant might be a null mutation as well or have very low residual activity. This is remarkable since *Lig4* knockout mice are embryonic lethal and so far in humans no complete *LIG4* deficiencies have been described. This case broadens the clinical spectrum of *LIG4* deficiencies.

Hum Mutat 34:1611–1614, 2013. Published 2013 Wiley Periodicals, Inc.\*

**KEY WORDS:** *LIG4*; immunodeficiency; primordial dwarfism; non-homologous end joining; NHEJ

The non-homologous end joining (NHEJ) pathway is involved in the repair of the DNA double-strand breaks. These can be generated during DNA replication, exposure to exogenous agents such as ionizing radiation (IR), or physiologically during V(D)J recombination, as happens during the early stages of B- and T-cell differentiation to generate antigen-specific B- and T-cell receptors. Defects

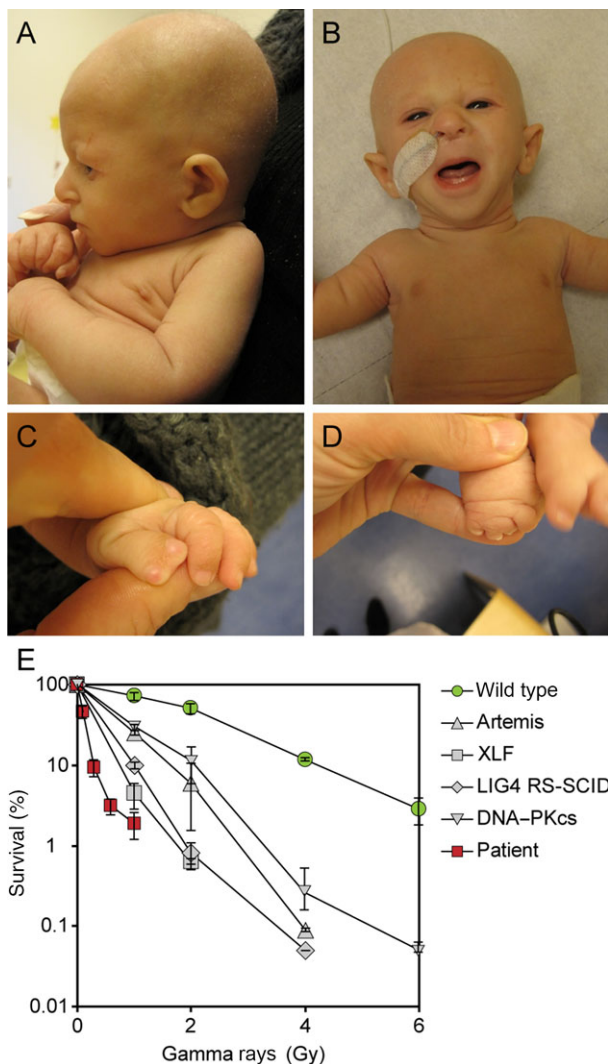
in NHEJ factors result in IR sensitivity, and in defects in V(D)J recombination leading to immunodeficiency. Genetic defects have been described in several NHEJ genes, including *DCLRE1C* (MIM #605988), *PRKDC* (MIM #600899), *NHEJ1* (MIM #611290), and *LIG4* (MIM #601837) [Moshous et al., 2001; Noordzij et al., 2003; O'Driscoll et al., 2004; van der Burg et al., 2009; van der Burg et al., 2006]. To date, 16 *LIG4* deficient patients have been described [Ben-Omran et al., 2005; Buck et al., 2006; Enders et al., 2006; Grunebaum et al., 2008; O'Driscoll et al., 2001; Riballo et al., 1999; Toita et al., 2007; Unal et al., 2009; van der Burg et al., 2006; Yue et al., 2013] (summarized in Supp. Table S1). All patients were IR sensitive, but clinically they can be divided into five distinct disease categories: (1) leukemia, (2) *LIG4* syndrome (MIM #606593), (3) Dubowitz syndrome (MIM #223370), (4) Omenn syndrome (MIM #603554), and (5) radiosensitive severe combined immunodeficiency (MIM #602450). Here, we present a male patient with a new clinical phenotype of *LIG4* deficiency characterized by microcephalic primordial dwarfism and neurological abnormalities.

The patient was born with extreme dysmaturity after 37 weeks of gestational age. At the age of 3 months, his height was 43 cm (−7.4 SD), weight was 1870 g (−8.9 SD), and head circumference was 29 cm (−8.9 SD). Besides the dysmaturity, the patient had several dysmorphisms (Fig. 1A and B) including hypotelorism, small viscerocranium, flat philtrum, thin upper lip, preaxial polydactyly (duplication of distal phalanx of left thumb), brachymesophalangy of the digits V on both hands, and partial cutaneous syndactyly of digits II–V of both feet (Fig. 1C and D), dysplastic kidneys with bilaterally vesicourethral reflux and urethral valves. Additionally, the patient had the neurological abnormalities, corpus callosum dysgenesis, and colpocephaly. At the age of 2 and 4 months, he suffered from a *Pseudomonas aeruginosa* and *Enterococcus faecalis* urinary tract infection, respectively, and he tested positive for *P. aeruginosa*, *P. jiroveci*, rhinovirus, norovirus, astrovirus, *Clostridium difficile*, and *Candida*. Besides the infectious complications, the first 3 months of life were characterized by feeding difficulties, diarrhea, failure to thrive, cholestatic icterus, tubulopathy, generalized erythema, and very dry cracked skin. Initially the patient seemed to recover from the opportunistic infections, but a second episode of an acute sepsis-like syndrome with respiratory insufficiency complicated by severe gastrointestinal bleeding—probably due to the development of thrombocytopenia—could not be successfully treated; the patient died at the age of 6 months.

Additional Supporting Information may be found in the online version of this article.

\*Correspondence to: Mirjam van der Burg, Erasmus MC, Department of Immunology's Gravendijkwal 230, Rotterdam 3015 CE, The Netherlands. E-mail: m.vandenburg@erasmusmc.nl

Contract grant sponsor: Sophia Kinderziekenhuis Fonds (grant 589 and Vidi grant 91712323).



**Figure 1.** Dysmorphic features of the face, hand, and feet and ionizing radiation sensitivity. The patient presented with facial dysmorphisms including beaked nose (A), hypotelorism, small viscerocranium, flat philtrum, and thin upper lip (B). In addition, the patient had a duplication of distal phalanx of left thumb, brachymesophalangy of the digits V on both hands (C), and partial cutaneous syndactyly of digits II–V of both feet (D). Clonogenic survival assay of wild-type (C570) fibroblasts and patients' fibroblasts deficient for Artemis, DNA-PKcs, XLF, or LIG4 (LIG4 SCID). The patient was extremely sensitive for ionizing radiation. Each curve represents the mean of at least two independent experiments. Error bars represent SEM (E).

Immunologic evaluation showed normal numbers of NK cells, very low B-cell numbers, and increased T-cell numbers (Supp. Table S2 and Supp. Materials and Methods). The increase in the number of T cells was mainly caused by an increase in the CD8+ T cells probably related to a viral infection. The presence of maternal T cells was excluded. Immunoglobulin (Ig) G was decreased, which was not secondary to malabsorption, whereas IgM and IgA were normal (Supp. Table S2) and Ig substitution therapy was initiated at the age of 4.5 months.

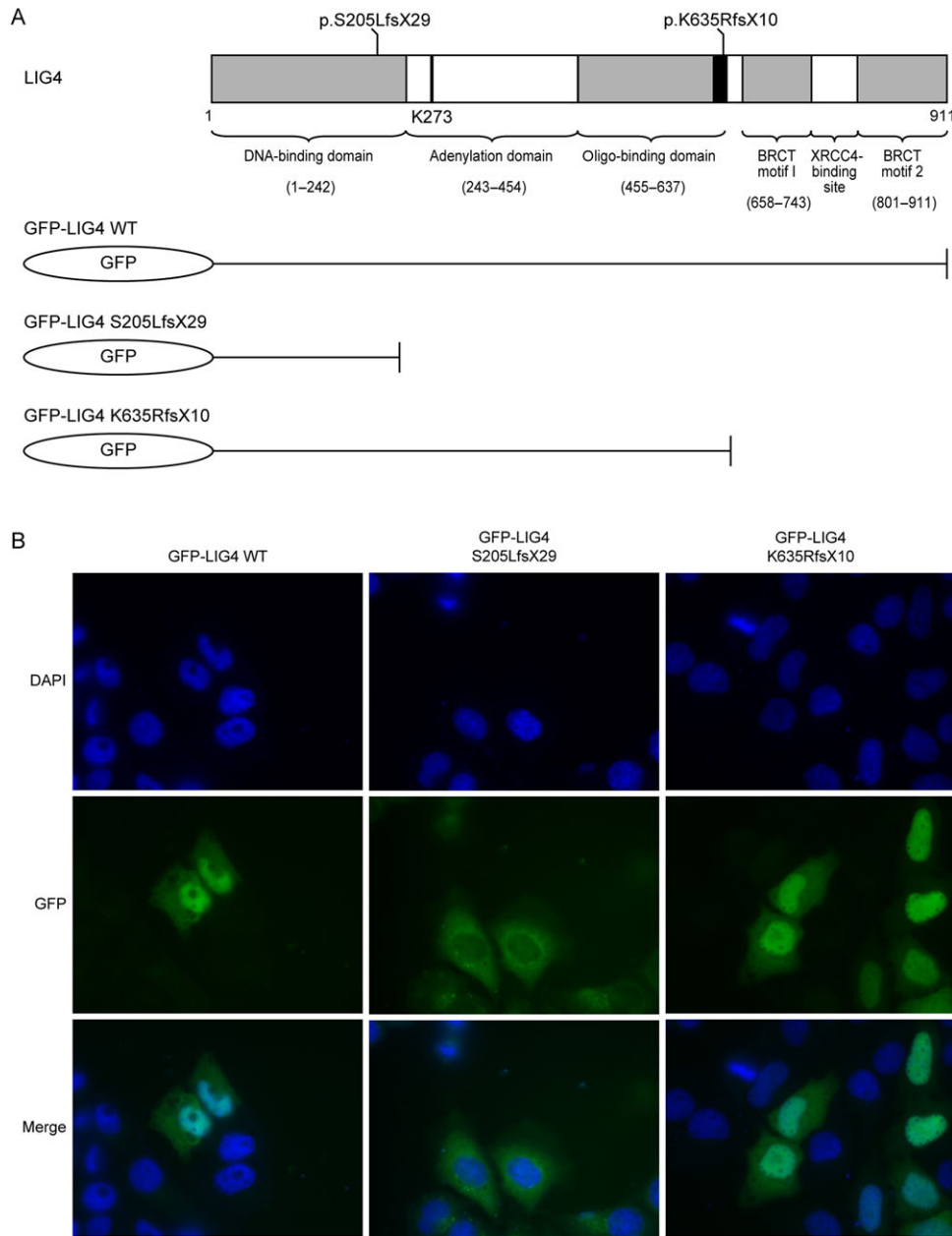
The clinical presentation, especially the immunodeficiency together with microcephaly was suggestive for a NHEJ defect. Therefore, the patient's fibroblasts were tested in a clonogenic survival assay (Supp. Materials and Methods). These were extremely IR sen-

sitive by an order of magnitude, c.f. the control at 10% survival (Fig. 1E) and even more sensitive than those of LIG4 and XLF deficient patients (three times more sensitive than the control at 10% survival), which are normally more IR sensitive than fibroblasts from Artemis and DNA-PKcs deficient patients (Fig. 1E). This result was indicative for a severe NHEJ defect.

Sequencing of the *LIG4* gene (Supp. Materials and Methods) showed the presence of two heterozygous single-nucleotide deletions in the *LIG4* gene (c.613delT and c.1904delA) (submitted to [www.lovd.nl/LIG4](http://www.lovd.nl/LIG4)). The first deletion was inherited from the mother and resulted in a frameshift and a premature stop codon in the DNA-binding domain (p.S205LfsX29). This mutation was recently described in the LIG4 patient presenting with the Dubowitz syndrome [Yue et al., 2013]. The mutant LIG4 protein lacks the nuclear localization signal (NLS), the active site, the adenylation domain, the oligo-binding domain, both BRCT motifs and the XRCC4-binding site (Fig. 2A). Since LIG4 exerts its function in the nucleus, we investigated the localization of the mutant LIG4 proteins by using green fluorescent protein (GFP)-tagged LIG4 expression constructs (Fig. 2A and Supp. Material and Methods). In contrast to wild-type LIG4, the S205LfsX29 LIG4 mutant was only expressed in the cytoplasm (Fig. 2B), which indicates that the S205LfsX29 mutant represents a null mutation.

The second paternally inherited deletion resulted in a frameshift, changing the last four amino acids of the NLS (K<sub>635</sub>K<sub>636</sub>V<sub>637</sub>I<sub>638</sub> → R<sub>635</sub>K<sub>636</sub>L<sub>637</sub>L<sub>638</sub>) without affecting the charge, and a premature stop codon (p.K635RfsX10). In this mutant, part of the NLS is retained, but it lacks both BRCT motifs and the XRCC4-binding site, which are necessary for the interaction with Cernunnos/XLF [Critchlow et al., 1997]. LIG4 interacts with XRCC4 and forms a 1:2 complex [Sibanda et al., 2001]. The interaction with XRCC4 is important since it stabilizes LIG4 protecting it from degradation [Bryans et al., 1999]. This implies that the p.K635RfsX10 mutant has probably very low residual activity or might even be a null mutant.

In our overexpression system, this mutant was still expressed in the nucleus (Fig. 2B) and is therefore consistent with the results of Girard et al. (2004) who found that deleting both BRCT motifs and the XRCC4-binding domain ( $\Delta 653-911$ ) still resulted in nuclear expression of the mutant LIG4 protein (Girard et al., 2004). None of the reported *LIG4* mutations in patients retains the NLS but lacks the XRCC4 interaction domain (Supp. Table S1 and Supp. Fig. S1). The p.R814X mutant lacks the BRCT 2 motif, but the NLS and XRCC4-binding site are present [Ben-Omran et al., 2005; O'Driscoll, et al., 2001]. This mutant is expressed in the nucleus and retained ~10%–15% residual double-strand ligation activity, but was barely detectable in the patient [O'Driscoll et al., 2001]. The estimated residual activity of this mutant is <1% [Girard et al., 2004]. The p.R580X mutant lacks the NLS and the XRCC4 interaction domain. Since this mutant is not stably expressed, does not interact with XRCC4, and does not enter the nucleus, it is considered to be a null mutant. Similar to the p.R580X mutant, the p.K635RfsX10 mutant lacks XRCC4-interacting domain [Critchlow et al., 1997], which is necessary for LIG4 stability and protection of LIG4 from degradation [Bryans, et al., 1999]. Based on these data and the severity of the clinical phenotype of the patient, we expect that this mutant has even less residual activity than the LIG4 mutants described before and might represent a null mutation. This is remarkable since LIG4 is considered to be essential for humans and LIG4 knockout mice are embryonic lethal [Barnes et al., 1998; Frank et al., 1998]. This study shows that LIG4 mutations affect the immune system or neurological development with different severity.



**Figure 2.** LIG4 mutants and their expression. Schematic representation of the LIG4 protein (NM\_001098268.1) and the GFP-LIG4 expression constructs. The different domains, active site (K273), and mutations identified in the patient are indicated. The nuclear localization signal (NLS1 [P<sub>623</sub>QEKKR<sub>629</sub>] and NLS2 [A<sub>630</sub>APKMKKV<sub>638</sub>] [Girard, et al., 2004]) is indicated in black. The numbers between brackets indicated the amino acid position (A). Localization of GFP-LIG4 wild type and mutants after transient transfection of U2OS cells (B).

## Acknowledgments

The authors thank S. de Bruin-Versteeg for making the figures and M.J. Moorhouse for critically reading the manuscript.

*Disclosure statement:* The authors declare no conflict of interest.

## References

- Barnes DE, Stamp G, Rosewell I, Denzel A, Lindahl T. 1998. Targeted disruption of the gene encoding DNA ligase IV leads to lethality in embryonic mice. *Curr Biol* 8:1395–1398.
- Ben-Omran TI, Cerosaletti K, Concannon P, Weitzman S, Nezarati MM. 2005. A patient with mutations in DNA Ligase IV: clinical features and overlap with Nijmegen breakage syndrome. *Am J Med Genet A* 137A:283–287.
- Bryans M, Valenzano MC, Stamato TD. 1999. Absence of DNA ligase IV protein in XR-1 cells: evidence for stabilization by XRCC4. *Mutat Res* 433:53–58.
- Buck D, Moshous D, de Chasseval R, Ma Y, le Deist F, Cavazzana-Calvo M, Fischer A, Casanova JL, Lieber MR, de Villartay JP. 2006. Severe combined immunodeficiency and microcephaly in siblings with hypomorphic mutations in DNA ligase IV. *Eur J Immunol* 36:224–235.
- Comans-Bitter WM, de Groot R, van den Beemd R, Neijens HJ, Hop WC, Groeneveld K, Hooijkaas H, van Dongen JJ. 1997. Immunophenotyping of blood lymphocytes in childhood. Reference values for lymphocyte subpopulations. *J Pediatr* 130:388–393.
- Critchlow SE, Bowater RP, Jackson SP. 1997. Mammalian DNA double-strand break repair protein XRCC4 interacts with DNA ligase IV. *Curr Biol* 7:588–598.
- Enders A, Fisch P, Schwarz K, Duffner U, Pannicke U, Nikolopoulos E, Peters A, Orłowska-Volk M, Schindler D, Friedrich W, Selle B, Niemeier C, et al. 2006. A

- severe form of human combined immunodeficiency due to mutations in DNA ligase IV. *J Immunol* 176:5060–5068.
- Frank KM, Sekiguchi JM, Seidl KJ, Swat W, Rathbun GA, Cheng HL, Davidson L, Kangaloo L, Alt FW. 1998. Late embryonic lethality and impaired V(D)J recombination in mice lacking DNA ligase IV. *Nature* 396:173–177.
- Girard PM, Kysela B, Harer CJ, Doherty AJ, Jeggo PA. 2004. Analysis of DNA ligase IV mutations found in LIG4 syndrome patients: the impact of two linked polymorphisms. *Hum Mol Genet* 13:2369–2376.
- Grunebaum E, Bates A, Roifman CM. 2008. Omenn syndrome is associated with mutations in DNA ligase IV. *J Allergy Clin Immunol* 122:1219–1220.
- Moshous D, Callebaut I, de Chasseval R, Corneo B, Cavazzana-Calvo M, Le Deist F, Tezcan I, Sanal O, Bertrand Y, Philippe N, Fischer A, de Villartay JP. 2001. Artemis, a novel DNA double-strand break repair/V(D)J recombination protein, is mutated in human severe combined immune deficiency. *Cell* 105:177–186.
- Noordzij JG, Verkaik NS, van der Burg M, van Veelen LR, de Bruin-Versteeg S, Wiegant W, Vossen JM, Weemaes CM, de Groot R, Zdzienicka MZ, van Gent DC, van Dongen JJ. 2003. Radiosensitive SCID patients with Artemis gene mutations show a complete B-cell differentiation arrest at the pre-B-cell receptor checkpoint in bone marrow. *Blood* 101:1446–1452.
- O'Driscoll M, Cerosaletti KM, Girard PM, Dai Y, Stumm M, Kysela B, Hirsch B, Gennery A, Palmer SE, Seidel J, Gatti RA, Varon R, et al. 2001. DNA ligase IV mutations identified in patients exhibiting developmental delay and immunodeficiency. *Mol Cell* 8:1175–1185.
- O'Driscoll M, Gennery AR, Seidel J, Concannon P, Jeggo PA. 2004. An overview of three new disorders associated with genetic instability: LIG4 syndrome, RS-SCID and ATR-Seckel syndrome. *DNA Repair (Amst)* 3:1227–1235.
- Riballo E, Critchlow SE, Teo SH, Doherty AJ, Priestley A, Broughton B, Kysela B, Beamish H, Plowman N, Arlett CF, Lehmann AR, Jackson SP, et al. 1999. Identification of a defect in DNA ligase IV in a radiosensitive leukaemia patient. *Curr Biol* 9:699–702.
- Sibanda BL, Critchlow SE, Begun J, Pei XY, Jackson SP, Blundell TL, Pellegrini L. 2001. Crystal structure of an Xrcc4-DNA ligase IV complex. *Nat Struct Biol* 8:1015–1019.
- Toita N, Hatano N, Ono S, Yamada M, Kobayashi R, Kobayashi I, Kawamura N, Okano M, Satoh A, Nakagawa A, Ohshima K, Shindoh M, et al. 2007. Epstein-Barr virus-associated B-cell lymphoma in a patient with DNA ligase IV (LIG4) syndrome. *Am J Med Genet A* 143:742–745.
- Unal S, Cerosaletti K, Uckan-Cetinkaya D, Cetin M, Gumruk F. 2009. A novel mutation in a family with DNA ligase IV deficiency syndrome. *Pediatr Blood Cancer* 53:482–484.
- van der Burg M, Ijspeert H, Verkaik NS, Turul T, Wiegant WW, Morotomi-Yano K, Mari PO, Tezcan I, Chen DJ, Zdzienicka MZ, van Dongen JJ, van Gent DC. 2009. A DNA-PKcs mutation in a radiosensitive T-B- SCID patient inhibits Artemis activation and nonhomologous end-joining. *J Clin Invest* 119:91–98.
- van der Burg M, van Veelen LR, Verkaik NS, Wiegant WW, Hartwig NG, Barendregt BH, Brugmans L, Raams A, Jaspers NG, Zdzienicka MZ, van Dongen JJ, van Gent DC. 2006. A new type of radiosensitive T-B-NK+ severe combined immunodeficiency caused by a LIG4 mutation. *J Clin Invest* 116:137–145.
- van der Burg M, Verkaik NS, den Dekker AT, Barendregt BH, Pico-Knijnenburg I, Tezcan I, van Dongen JJ, van Gent DC. 2007. Defective Artemis nuclease is characterized by coding joints with microhomology in long palindromic-nucleotide stretches. *Eur J Immunol* 37:3522–3528.
- Yue J, Lu H, Lan S, Liu J, Stein MN, Haffty BG, Shen Z. 2013. Identification of the DNA repair defects in a case of Dubowitz syndrome. *PLoS One* 8:e54389.