

Key words: Dual Energy x-ray absorptiometry, precision, atypical femoral fracture, in-vivo,

Abstract:

Background: Atypical femoral fracture (AFF) is documented as a known but rare complication of bisphosphonate use for the treatment of osteoporosis. These present in an incomplete form prior to failure, which results in a complete fracture requiring surgical intervention. Dual energy x-ray absorptiometry (DXA) is the gold standard for the diagnosis of Osteoporosis and for monitoring the response to therapeutic interventions. This provides an opportunity to use routine DXA scans to identify incomplete atypical fractures, which can subsequently be monitored for progression and pre-fracture intramedullary nailing undertaken where necessary. DXA manufacturers have developed extended femur scans to assess and measure the femoral cortex for incipient atypical femoral fractures. The aim of this study was to evaluate the precision errors related to the cortical measurements and for hip bone mineral density using the extended femur setting.

Methodology: A single operator performed duplicate same day in-vivo measurements of the femur in 30 consenting participants, with repositioning between scans, during their visit for routine DXA scanning. The study was performed on a single GE Lunar Prodigy scanner (GE Lunar, Bedford, UK). Root mean squared standard deviation (RMS SD) and coefficient of variation (RMS CV%) were calculated for the cortex measurements known as beaking index (BI) and hip bone mineral density (BMD) measurements.

Results: The use of the extended femur scan software yielded an RMS SD (RMS CV%) of 0.011 (1.43%) for the total hip and 0.015 (2.05%) for the femoral neck. The BI measurement RMS SD (RMS CV%) was 0.473 (38.10%) Visual assessment of the femoral cortex discounted all positive BI anomalies as software generated in this dataset.

Conclusions: The use of extended femur scan software did not affect the precision errors of the BMD measurements at the hip when compared to the literature on focused hip scans. The BI precision errors were much greater and therefore unreliable unless accompanied by visual assessment which is recommended to avoid unnecessary investigation in around one fifth of the scan population.

Introduction

Osteoporosis can be literally translated as porous bones, leading to structural deterioration of the bone coupled with a reduction in bone density, increasing the risk of fracture [1]. With untreated osteoporosis, the quantity and quality of the bone deteriorates and becomes vulnerable to fracture at much lower forces than would normally be expected. Dual energy x-ray absorptiometry (DXA) scanning is widely recognised as the gold-standard imaging modality for the measurement of bone mineral density (BMD) used to aid diagnosis, management and treatment response of osteoporosis medications [2].

Atypical femoral fractures are differentiated from these standard fractures by the presence of fracture in the absence of trauma, increased cortical thickness in many cases, and originate in the lateral cortex of the femur. Atypical femoral fracture, is classified as being extracapsular, not affecting the hip joint, and at or distal to the subtrochanteric area.

Atypical femoral fractures (AFFs) have been associated with the long term use of bisphosphonate drugs used to treat osteoporosis and were first described in the seminal paper as being atraumatic and occurring in the presence of long term bisphosphonate therapy [3]. Numerous subsequent studies have demonstrated similar findings, highlighting the significant morbidity associated with these types of fractures [4-7]. However, prior to complete fractures, there are often warning signs. Patients may report persistent groin, thigh or hip pain and on imaging “beaking” can

be visualised on the lateral aspect of the femur. These early features provide the potential for opportunistic screening for AFF using dual energy x-ray absorptiometry (DXA) as a low dose imaging technique where patients will be scanned routinely, as a means of monitoring their response to osteoporosis treatment and assessment. Incomplete AFFs have been identified on imaging through thickening of the lateral femoral cortex, presenting as a peak. New DXA scanning software, developed by General Electric (GE) Lunar, presents the ability to routinely scan and assess the full length of the femur and highlight cortical changes as part of routine clinical care. Designed to be used as part of routine DXA scanning to identify changes in the femoral cortex, these scans aid the identification of cortical changes which may signify incomplete atypical femoral fractures.

GE Lunar conducted a study involving extended femur bench phantoms using the new version 17.0 scan software, however an in-vivo precision study offers a true reflection of measurement differences found in human subjects. The motivation for this precision study is the evaluation and assessment, in routine clinical use, of the extended femur scanning software developed by GE, designed to be used as part of routine DXA scanning, to identify changes in the femoral cortex in a clinical population.

Methods

Materials and methodology

An in-vivo precision study was conducted to evaluate the repeatability of measurements of the beaking index, a measurement of expanded cortical thickness in the femoral shaft, and to evaluate any impact on hip BMD measurements from the new extended femur scan. A single operator in-vivo precision study was undertaken in order establish whether any measurement differences were found in humans, in contrast to the results of the phantom measurements found by GE using the same software. Daily testing of scanners in accordance with manufacturers best practice was conducted, using the calibration block and encapsulated aluminium spine phantom, both as supplied by GE Lunar.

Participants

This single centre precision study invited adults ≥ 20 years referred for DXA scanning to participate in the study. Exclusion criteria were bilateral total hip replacements, < 20 years of age or those not able to give informed consent. Scanning of the extended femur would not occur in patients under the age of 20 years, as the femoral epiphyses may not have fused prior to this age rendering any result unreliable.

Recruitment was planned for 30 participants, with study information sent to 75 participants, in the assumption that approximately 50% of those would consent to participate [8]. A minimum of 30 participants should be included in a precision study, with duplicate scans, to obtain statistically valid results [9]. It is a recommendation of

the International Society for Clinical Densitometry (ISCD) that 30 degrees of freedom are used to assess short term precision in DXA measurement, scanning 30 patients, representative of the typical scan population within the department, in duplicate [10]. Same day duplicate scans pose least inconvenience for participants.

Study approvals were obtained from the National Research Ethics Service and the hospital trust Research and Development department, as the study involved exposing patients to an additional radiation burden, NHS Grampian research and development clinical effectiveness no. 4194, North of Scotland Research reference 19/NS/0183, University of Exeter sponsor no. 1819/42, Integrated Research Application System no. 259999.

Methods

All eligible patients were sent an invitation letter to participate in the study and a participant information sheet in addition to their standard clinic appointment letter, routinely sent out in advance. Written informed consent was obtained at the time of the scan appointment.

All participants personal details were checked against departmental records, measurements of height in centimetres (cm) to the nearest 0.001cm using a Holtain stadiometer (Crymych, Dyfed, UK) and weight in kilograms (kg) to nearest 0.1kg using Marsden professional digital scales (Rotherham, UK) are taken as part of routine care. All scans were performed on a single GE Lunar Prodigy DXA scanner with version 17.0 software (GE Healthcare, Bedford, UK). Patient preparation followed standard clinical care, with removal of underwired bras, jeans, piercings and any clothing with metal studs/zips/decoration which may interfere with scan measurements.

The participant was asked to lie centrally on the scanner bed, and scans were taken of each extended femur individually, then a scan of the lower spine (three individual scans) as per standard practice. For the extended femur scans, as for proximal hip scanning, a rigid plastic positioner is used to position the legs. This is supplied with the scanner by GE, fitted with Velcro to support the feet, allowing the patient to relax the leg muscles. The purpose of this is to rotate and abduct the femur, and it is used as standard to ensure reproducible images and results. The images acquired are used initially to ascertain straightness and centralisation of the femur, and alterations in positioning are made until the femur is straight and central in the scanner field of view.

After this process, the participant was asked to alight from the scanner bed, then lie back down. A further scan of each extended femur was taken (two additional scans) in the same manner as the first. All measurements were obtained by a single operator to reduce inter-operator precision error influencing the measurements. Following the scan, the participant was provided with a clinical diagnosis via the referring clinician as per standard clinical protocol.

Scan analysis.

All scans were analysed by the operator, following the departmental protocol. As part of the extended femur scan analysis, the regions of interest should be considered as follows: acetabulum is fully visualised, adequate visualisation above the greater trochanter, recommended as two to three sweeps. All four corners of the

femoral neck box should be located in soft tissue, no ischium mapped as bone in femoral neck box and the mid femoral line should bisect the femoral head, running from the greater trochanter through the fovea capita to the pelvic brim. The neck box should be perpendicular to the femoral shaft. If there are any changes made to the size, position or angulation of the neck of femur box, the search button should be used to return the box to the point of lowest BMD. The femur should be central, straight and vertical in the field of view, at the proximal end the lesser trochanter should be minimised as far as patient habitus allows; at the distal end there should be no patella or supracondylar flare in the scan field.

Data analysis

Inter-operator precision error at total hip and femoral neck were calculated for scans performed using the extended femur scan setting. The root mean square standard deviation (RMSSD) and root mean square coefficient of variation (RMSCV%) were calculated using the ISCD online advanced precision calculator. The precision measurements of beaking index were calculated using the same program. The LSC was calculated by multiplying the precision error RMS CV% by 2.77, and the resultant figure indicates the change in BMD that should be considered as statistically significant for a true biological change rather than one manufactured by the equipment, operator and changes in patient positioning. Accepted figures quoted by the ISCD for 95% least significant change (LSC) for femoral neck is 6.9%, and total hip 5.0% [11]. A Bland-Altman plot was used to display the differences between sets of beaking index measurements, with agreement between measurements and 95% confidence interval calculated, as seen in figure 1.

Results

Participant demographics

The participant group for this study had an age range of 49-89 years; participant characteristics are displayed in table 1. Male participants made up 37% of the total scanned, participants had a median age of 70 years, and had a median BMI of 26.8. Three female participants and one male participant were found to be osteoporotic.

Table 1. Participant characteristics – in-vivo precision study.

Precision calculations.

As displayed in table 2, the actual figures for femoral neck precision of 5.68% and 3.96% for total hip measurement. The mean and difference of beaking index measurement error were calculated using the Bland-Altman method of 95% limit of agreement [12] and plotted as shown in figure 1.

Table 2. In-Vivo precision study results at total hip and neck of femur BMD and beaking index values.

Figure 1. Bland-Altman plot displaying the precision study beaking index, measurements in millimetres.

As demonstrated by the Bland-Altman plot in figure 1, 28 of 30 duplicate beaking index measurements fell within two standard deviations (SD) of the mean, or 93.3%. This is only marginally lower than the expected 95% of points falling within two SD of the mean [13]. Six participants exhibited a mean beaking index measurement greater than 1mm, and six of 30 participants had a beaking index measurement difference greater than 0.5mm, quoted by GE as the error margin of measurements. The error margin of the beaking index measurement using bench phantoms was set at 0.5mm by GE, with a caveat that measurement error may be higher in a clinical population, which was untested [14]. This in-vivo precision study found the mean of the measurements on human participants to be 0.5mm.

Outliers in beaking index measurement.

One set of beaking index scan results for a female participant demonstrated a software inaccuracy in identifying the cortex of the femur, displaying a result of 4.2 mm in one scan, and 1mm in the subsequent scan. This measurement of beaking index difference was found to be out with two standard deviations, attributed to erroneous placing of cortical borders by scan software, perhaps confounded by a slight change in patient positioning.

The second outlier was similarly placed, with the scan software identifying a thickening at the endosteal border of the lateral femoral cortex on one scan. Six patients scanned were found to have mean beaking index measurements greater than 1mm; however no features suggestive of peaks or cortical thickening were identified on any scan image.

One of these scan pairs demonstrated an irregularity in the positioning of the femoral cortical margin, where the endosteal border of the lateral femoral cortex is incorrectly identified by the scan software. This created a step which the software analyses as a cortical thickening or peak.

In some cases, there was substantial measurement variation between pairs of beaking index scans, no reason was found for this aside from erroneous placement by the automated scan software, as both scans appeared very similar visually.

There is no option for operator placement or variation of measurement points within the current scan software version.

Discussion

The results of this in-vivo precision study demonstrate the use of GE extended femur scan software does not adversely influence the measurement of BMD at the hip using DXA, and supports the routine use of this software in clinical practice when extended femur scans are deemed appropriate. However, the precision error relating to the beaking index was much greater due to software inaccuracies in some participants. In these cases, the misplacement of the cortical edge-detection is readily visualised and based on this, it is therefore recommended that visual analysis is used to supplement beaking index measurements using the GE Lunar software. None of the participants were found to demonstrate beaking on DXA imaging when visually assessed.

In support of this, several studies conducted using existing manufacturers hip scan software found no detriment to BMD results in the extension of scan length, using both Hologic and GE scanners [15, 16]. One study found that although there was a small difference between short and long femur scan fields, the difference was still well within the precision error limits[16].

The age range of participants was 49 – 89 years, closely matched to the age range of the routine clinical population, identified as prerequisite of best practice precision measurements [17]. The precision error of DXA scan measurements is thought to be independent of age and BMD, however may increase in the more elderly population due to age-related degenerative changes[12].

Ethnicity of participants was broadly in keeping with the settled Caucasian population of the area, however this may limit the comparability of the results in other areas with a more diverse ethnic populations.

Participant BMI was identified as a confounding factor for precision error, with BMI >30 identified in previous works as influencing precision measurements[18]. This is thought to be as a consequence of non-uniform distribution of soft tissue, and replication of this distribution between scans. There is no consensus on whether panniculus retraction leads to raising or lowering of BMD, however a change of +/- 2% has been identified [18]. To aid replication, the non-retraction of the panniculus is standard practice within the department.

Longitudinal in-vivo precision measurements offer the most accurate and reliable way of calculating precision error, however there are logistical barriers to this, and

higher rates of patient attrition for various reasons [19]. A short term in-vivo precision study offers a convenient way for patients to participate in research without being inconvenienced by returning for further assessment. In either situation, in-vivo studies are more representative of patient population, with wider variance due to inhomogeneity of human tissue.

The extended femur scanning software provides an opportunity to combine cortical assessment of femur through an extended DXA scan covering the femur, in addition to routine bone mineral density measurements at the hip. It has been established that this has no detrimental effect on the BMD measurements, and with the addition of less than two minutes to the examination time of a dual extended femur scan, and 37 μGy to the cumulative radiation dose, it is not a major burden of time or radiation for the patient or for service delivery. However, the precision errors relating to the BI in this study demonstrate that the automated analysis of these scans should not be used to trigger further investigations and visual assessment is essential to ascertain whether an identified “beak” is a software error or a clinically significant finding, which requires further imaging.

Conclusions

The in-vivo short term precision study undertaken provides reassurance that the primary use of the scanning software in obtaining measurements of total hip and femoral neck BMD is not adversely affected by the use of the new extended femur software with scanning using the extended femur option. The precision errors for the

BI were much greater than those for BMD measurements from the same study. The BI precision errors are above acceptable limits and underpin the recommendations for visual assessment of the femoral cortex without over-reliance on the software.

Further research: A large scale in-vivo precision study encompassing all operators and scanners associated with the department would add statistical power to the work already completed, provide ongoing quality assurance and ensure consistency between operators and throughout departments.

References:

1. *Consensus development conference: Diagnosis, prophylaxis, and treatment of osteoporosis*. The American Journal of Medicine, 1993. **94**(6): p. 646-650.

2. Blake, G.M. and I. Fogelman, *The role of DXA bone density scans in the diagnosis and treatment of osteoporosis*. Postgraduate Medical Journal, 2007. **83**(982): p. 509-517.
3. Odvina, C.V., et al., *Severely Suppressed Bone Turnover: A Potential Complication of Alendronate Therapy*. The Journal of Clinical Endocrinology & Metabolism, 2005. **90**(3): p. 1294-1301.
4. Compston, J., *Pathophysiology of atypical femoral fractures and osteonecrosis of the jaw*. Osteoporosis International, 2011. **22**(12): p. 2951-2961.
5. Schilcher, J., *High revision rate but good healing capacity of atypical femoral fractures. A comparison with common shaft fractures*. Injury, 2015. **46**(12): p. 2468-2473.
6. Oh, C.-W., et al., *Prophylactic nailing of incomplete atypical femoral fractures*. TheScientificWorldJournal, 2013. **2013**: p. 450148-450148.
7. Wilson, P., Heyburn, G., *Management of atypical femoral fractures*. . GM Journal, 2017. **47**(11).
8. A. Thoma, F.F., L. McKnight, M. Bhandari, *How to optimize patient recruitment*. Canadian Journal of Surgery, 2010. **53**(3): p. 205-210.
9. Glüer, C.C., et al., *Accurate assessment of precision errors: How to measure the reproducibility of bone densitometry techniques*. Osteoporosis International, 1995. **5**(4): p. 262-270.
10. Baim, S., et al., *Precision Assessment and Radiation Safety for Dual-Energy X-Ray Absorptiometry: Position Paper of the International Society for Clinical Densitometry*. Journal of Clinical Densitometry, 2005. **8**(4): p. 371-378.

11. Shepherd, J.A., et al., *Cross-Calibration and Minimum Precision Standards for Dual-Energy X-ray Absorptiometry: The 2005 ISCD Official Positions*. Journal of Clinical Densitometry, 2006. **9**(1): p. 31-36.
12. El Maghraoui, A., et al., *Reproducibility of bone mineral density measurements using dual X-ray absorptiometry in daily clinical practice*. Osteoporosis International, 2005. **16**(12): p. 1742-1748.
13. Altman, D.G. and J.M. Bland, *Standard deviations and standard errors*. BMJ, 2005. **331**(7521): p. 903.
14. General Electric Company, *Using GE Lunar DXA to quantify, visualise and trend incipient atypical femoral fractures*. 2017, GE Healthcare.
15. Prater, G.L., et al., *The Effect of Extending Femur Scan Length on BMD Results on the Hologic Discovery-W Scanner*. Journal of Clinical Densitometry, 2014. **17**(4): p. 518-521.
16. McKiernan, F.E., et al., *A Long Femur Scan Field Does Not Alter Proximal Femur Bone Mineral Density Measurements by Dual-Energy X-Ray Absorptiometry*. Journal of Clinical Densitometry, 2011. **14**(3): p. 354-358.
17. Kim, H.-S. and S.-O. Yang, *Quality Control of DXA System and Precision Test of Radio-technologists*. Journal of bone metabolism, 2014. **21**(1): p. 2-7.
18. Binkley, N., D. Krueger, and N. Vallarta-Ast, *An Overlying Fat Panniculus Affects Femur Bone Mass Measurement*. Journal of Clinical Densitometry, 2003. **6**(3): p. 199-204.
19. Jankowski, L.G., et al., *Cross-calibration, Least Significant Change and Quality Assurance in Multiple Dual-Energy X-ray Absorptiometry Scanner Environments: 2019 ISCD Official Position*. Journal of Clinical Densitometry, 2019. **22**(4): p. 472-483.

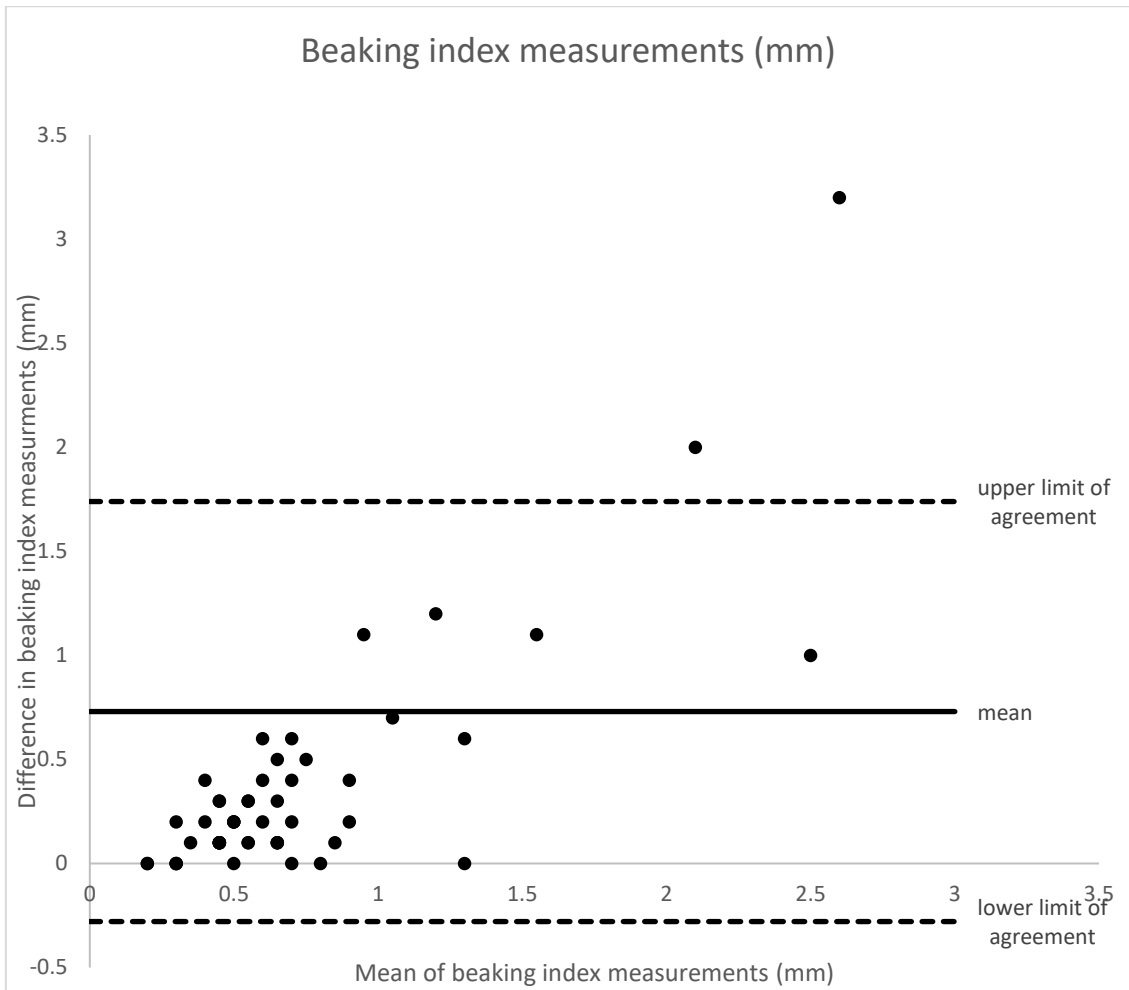


Figure 1. Bland-Altman plot displaying the precision study beaking index, measurements in millimetres.

Table 1. Participant characteristics – in-vivo precision study.

	Male (11)	Female (19)
Median age yrs. (range)	70 (49-78)	67 (49-89)
Median height cm (range)	175.4 (163.6-177.6)	157.9 (148.5-175)
Median weight kg (range)	86 (71-130.9)	68.75 (47.5-100)
Median BMI kg/m ² (range)	29.8 (24-42)	26.5 (20.4-36.8)
Osteoporotic on scan (%)	1 (9.1)	3 (15.8)
Osteopenic on scan (%)	3 (27.3)	13 (68.4)
Normal BMD on scan (%)	7 (63.6)	3 (15.8)
Patients with mean Beaking index >1mm (%)*	4 (36.4)	2 (10.5)

* A >1mm beaking index indicates a possible incomplete AFF

Table 2. In-Vivo precision study results at total hip and neck of femur BMD and beaking index values.

	Total hip	Neck of femur	Beaking Index
	BMD	BMD	(mm)
RMS SD	0.011	0.015	0.473
RMS CV	1.43	2.05	38.18
LSC %	3.96	5.68	

RMS - Root mean squared, SD – Standard deviation, CV – coefficient of variation, BMD – bone mineral density, mm – millimetres.