

RESEARCH ARTICLE

Violence in Hasmonean Judea: Skeletal evidence of a massacre from 2nd–1st century BCE Jerusalem

Jenna M. Dittmar^{1,2}  | Yossi Nagar³  | Kfir Arbiv^{3,4} | Tehillah Lieberman^{3,5} | Piers D. Mitchell⁶ 

¹Department of Archaeology, University of Aberdeen, Aberdeen, UK

²Darwin College, University of Cambridge, Cambridge, UK

³Israel Antiquities Authority, Jerusalem, Israel

⁴Department of Archaeology, Tel Aviv University, Tel Aviv, Israel

⁵Department of Land of Israel Studies and Archaeology, Bar Ilan University, Ramat Gan, Israel

⁶Department of Archaeology, University of Cambridge, Cambridge, UK

Correspondence

Jenna Dittmar, Department of Archaeology, University of Aberdeen, Aberdeen, UK.
Email: jenna.dittmar@abdn.ac.uk

Funding information

Darwin College, University of Cambridge

Abstract

During a salvage excavation conducted by the Israel Antiquities Authority, a mass grave containing the skeletal remains from 124 individuals, many with evidence of weapon injuries, was discovered in a water cistern outside the Old City of Jerusalem. Radiocarbon dates derived from human bone and the date of the material finds suggest the skeletal remains date to the end of the 2nd century or the beginning of the 1st century BCE. The aim of this research is to analyze the weapon injuries in order to reconstruct the nature and context of this violence. The human skeletal remains from 23 individuals recovered from the cistern were selectively retained and examined macroscopically in a laboratory setting. Silicone casts of selected weapon injuries ($n = 5$) were analyzed using scanning electron microscopy. Numerous examples of peri-mortem blunt- and sharp-force trauma were observed including evidence that at least 16 individuals were decapitated. The extent and nature of the observed injuries as well as the evidence of their haphazard deposition into the cistern suggest that these individuals were the victims of a massacre. As a highly visible act of violence, massacres are often used as a mechanism for social control. When contextualized, this skeletal assemblage is most likely evidence of a massacre that occurred during the reign of the Hasmonean king Alexander Jannaeus. This is the first archeological evidence for the use of socially sanctioned violence to legitimize the Hasmonean state and to maintain social control at the end of the 2nd century–early 1st century BCE.

KEYWORDS

Alexander Jannaeus, decapitation, indiscriminate violence, mass grave, weapon injuries

1 | INTRODUCTION

Throughout its long history, Jerusalem has served as a major political, cultural, and religious center: a tradition that continues through its importance to the three monotheistic religions. Due to its importance and strategic position, the city has a turbulent history with many

rulers occupying and controlling the region. As a result of these contests, the city has been attacked, captured, and recaptured numerous times; besieged; and completely destroyed at least twice. Yet, surprisingly, little skeletal evidence of Jerusalem's turbulent past prior to the Middle Ages has been uncovered. In 2017, the Israel Antiquities Authority conducted a salvage excavation at the Russian Compound

This is an open access article under the terms of the [Creative Commons Attribution-NonCommercial](https://creativecommons.org/licenses/by-nc/4.0/) License, which permits use, distribution and reproduction in any medium, provided the original work is properly cited and is not used for commercial purposes.

© 2022 The Authors. *International Journal of Osteoarchaeology* published by John Wiley & Sons Ltd.

(in Hebrew: Migrash HaRusim) which is located just outside the present-day Old City of Jerusalem (Lieberman et al., 2020). During the excavation, a large number of human skeletal remains, many that had evidence of weapon injuries, were discovered in a disused water cistern. Analysis of pottery fragments that were intermingled with the human remains indicate that the bodies were probably deposited into the cistern during the late 2nd century–early 1st century BCE. It has been proposed that the skeletal remains represent the aftermath of a violent encounter that may have occurred during the Hasmonean Era (see Lieberman et al., 2020).

The Hasmoneans were a Jewish family that rose to power after fighting against the Seleucid rulers in the mid-2nd century BCE (Atkinson, 2016; Regev, 2013). The Hasmonean dynasty (152–63 BCE) was characterized by instability and violence that was preceded by a series of successive revolutions that began in 175 BCE. Descriptions of the conflict between the Hasmonean rulers and the Pharisees as well as the sectarian disputes, detailed in contemporary texts, all reflect the turbulent social climate and use of violence to precipitate the subjugation of the masses (Babota, 2020; Bar-Kochva, 2019). Yet, until now, minimal archeological evidence has been found to corroborate this.

The aim of this research is to analyze the weapon injuries in detail in order to reconstruct the nature and context of this violence. By studying the pattern of injuries and the weapons used together with the age and sex of the individuals involved, it is possible to

differentiate between wounds that were likely inflicted during a battle versus those that occurred as the result of a different kind of violent encounter. The factors that contribute to violence are complex and often involve a combination of social and political impetuses (Fox et al., 2002; Sampson & Groves, 1989). By placing the findings of this research into the historical context, a more comprehensive understanding of the socio-political landscape during the Hasmonean period can be obtained.

2 | MATERIALS AND METHODS

2.1 | Materials

The Russian Compound is situated on a hill approximately 300 m northwest of the corner of the present-day city wall and north of Jaffa Street, the modern thoroughfare that preserves the ancient main highway that led from Jerusalem to coastal Jaffa (Joppa) (Arbiv et al., 2018) (Figure 1). The excavation was carried out by the Israel Antiquities Authority and funded by the Bezalel Academy of Art and Design. During the excavation, a water cistern was identified that consisted of a natural, asymmetrical cavity, which was worked to store rainwater and overland flow (Figure 2a,b).

When excavated, four distinct strata were identified in the cistern (Figure 2a). The fill in the topmost layer (I, L.100) contained ceramic

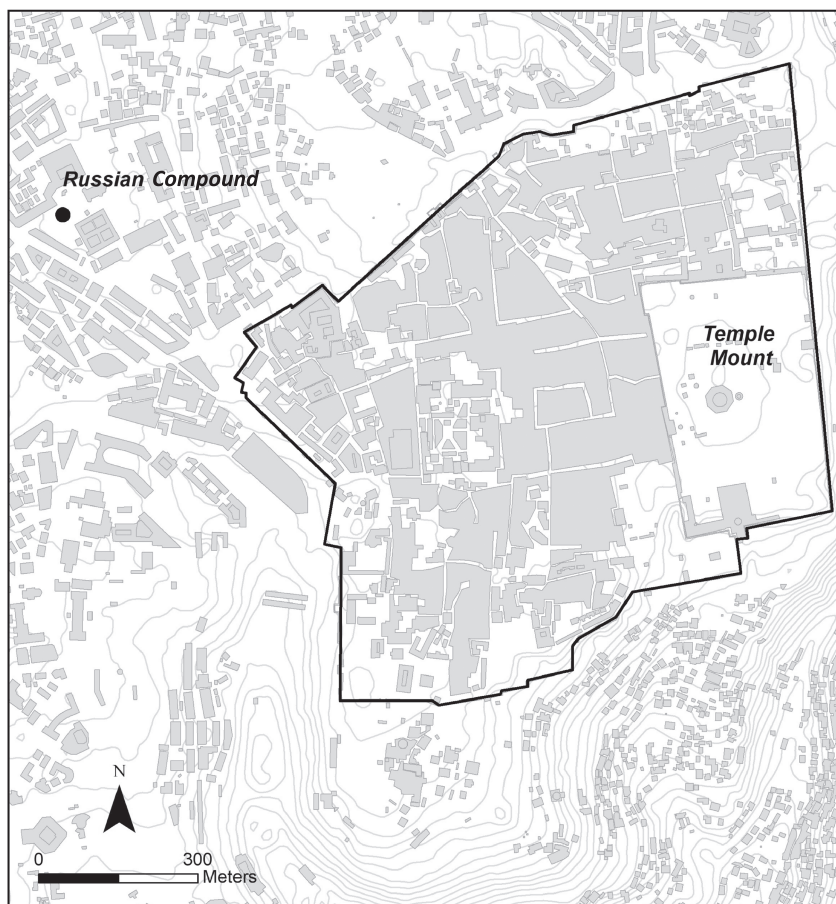



FIGURE 1 Map showing the location of the Russian compound in relation to the Jerusalem city wall. Image credit: Israel Antiquities Authority

FIGURE 2 (a) Cross-sectional plan of layers in the cistern (context: A7929); layer III equates to L.112, and the scale shows height above sea level in centimeters (cm). (b) Cistern after excavation. (c) Horizontal layer of human remains during the excavation. Image credit: (a) O. Rose and (b, c) K. Arbiv [Colour figure can be viewed at [wileyonlinelibrary.com](https://onlinelibrary.wiley.com/doi/10.1002/oa.3084)]



sherds that first appeared in the late 1st century BCE and that were common during the 1st century CE. Consequently, the sealing of the cistern should be dated no earlier than the last third of the 1st century BCE or early 1st century CE. Layer II (L.101, 111) contained cremated human skeletal remains from at least 32 individuals as well as large amounts of ash and charcoal. Evidence of cremation in ancient Israel is usually associated with Roman occupation. This layer also contained numerous ceramic sherds from storage jars and cooking pots, as well as several metal objects including the handle

of a bronze jug, nails, a scale of armor, and part of a horse bridle. The chronological horizon inferred by the ceramic assemblage in layer II is mid-1st century BCE (Lieberman et al., 2020). This is supported by the presence of artifacts from Roman military personnel. The remainder of this paper will focus on layer III (L.112), which contained the skeletal remains of at least 124 individuals (see Figure 2c) (see Lieberman et al., 2020). However, only a subset of the skeletal remains found in layer III is discussed within this work (detailed below).

The age-at-death data for all individuals recovered from layer III is summarized in Table 1. The methods used to estimate age-at-death and biological sex have been previously published in Lieberman et al. (2020). The skeletal assemblage consisted of partly articulated skeletons and disarticulated elements. Several of the partially articulated skeletons were positioned in a way that suggests that the bodies were thrown into the cistern, rather than intentionally placed. Layer III was separated from layer II above it by a layer of stones that were used to cover the bodies and seal layer III. The intermingling of body parts, coupled with the presence of weapon injuries throughout the skeletal remains in layer III, suggests that all individuals were deposited within a relatively short period of time and likely represent individuals that died during the same historical event (Lieberman et al., 2020).

The majority of the human skeletal remains were assessed in the field and then immediately reburied, as per the regulations in Israel (Nagar, 2002). During this assessment, evidence of skeletal trauma including weapon injuries, was identified on several individuals. It was not possible to wash the skeletal remains prior to analysis in the field, so it is likely that further examples of trauma were present but could not be identified during this initial assessment. A sample of skeletal elements, most of which had evidence of trauma, was temporarily retained for further analysis and later reburied. The skeletal material assessed within this study is believed to be from 23 distinct individuals, but due to the nature of the assemblage, it is possible that some of the elements could have come from the same individuals. The sample consisted of 8 crania or partial crania, 10 mandibles, 31 vertebrae, 1 partial first rib, and 1 fragment of a femur shaft. All of the skeletal elements that were retained for analysis were those of adults.

In addition to the human skeletal remains uncovered in layer III (L.112), a variety of fragmented pottery sherds and restorable vessels were recovered including those of bowls, saucers, storage jars, and flasks, as well as a spindle whorl and a mold-made lamp. The ceramic assemblage can be dated to the late 2nd century–early 1st century BCE. The finds within this layer are very similar to assemblages found in the Hasmonean palaces in Jericho, particularly in buildings and contexts dated to the reign of King Alexander Jannaeus (103–76 BCE), (Bar-Nathan, 2002, pp. 3–20), where numismatic finds served as a chronological anchor for the dating of the assemblages (Lieberman et al., 2020).

2.2 | Methods

The skeletal material that could be studied in the laboratory was assessed macroscopically using a hand lens (10×) to magnify the

margins of the traumatic injuries to determine if an injury occurred ante-, peri-, or post-mortem (Moraitis & Spiliopoulou, 2006; Sauer, 1998; Ubelaker & Adams, 1995; Walker, 2001). The morphological characteristics of the observed trauma were described and used to classify the mechanism (e.g., sharp-force, blunt-force). Sharp-force trauma is produced by a tool that is edged, pointed, or beveled, while blunt-force trauma is produced by low velocity impact from a blunt object or the low-velocity impact of a body with a blunt surface (Galloway et al., 2014; Loe, 2017; SWGANTH, 2011). If the traumatic injuries identified were consistent with sharp-force trauma, the characteristics of the lesions were then used to classify the type of bladed weapon used to inflict the trauma, according to descriptions by Lewis (2008) for knife cut marks and sword wounds and by Alunni-Perret et al. (2005) for hacking trauma and/or hatchet chop marks.

Silicone casts of five well-preserved sharp-force injuries were made using RTV Putty Silicone (Alec Tiranti Ltd., London) following the procedure outlined in Dittmar et al. (2015). These casts were analyzed to obtain the morphological characteristics of the tool marks using a Hitachi TM3000 tabletop scanning electron microscope (SEM) located in the McDonald Institute for Archaeological Research at the University of Cambridge, UK. Scanning electron microscopy was performed to enhance visualization of the topographical features and increase the depth of field to reveal variations that are not always visible with the naked eye or with light microscopy (Tucker et al., 2001).

2.3 | Dating

Teeth from two adult individuals (H-1 and H-12) were radiocarbon dated at the SUERC radiocarbon laboratory, following their standard procedures (Dunbar et al., 2016). Calibration was undertaken using OxCal v. 4.4 (Bronk Ramsey, 2009; Bronk Ramsey & Lee, 2013) and the IntCal20 calibration curve (Reimer et al., 2020) (Figure 3). For a number of reasons, the date ranges derived from radiocarbon dating are likely older than the actual date when the individual died. The date derived from a tooth represents the period of time during which that tooth formed during childhood and not the date that an individual died. To compensate for this, the radiocarbon date was adjusted to account for the time between the development of the tooth and the age at which the individual died. H-1 was estimated to be 20–29 years old at the time of their death, and H-12 was estimated to be an old adult (50+). Therefore, the date of death for H-1 was conservatively adjusted by 20 years to

TABLE 1 Age-at-death distribution of the skeletal remains found in layer III (Lieberman et al., 2020)

	Age-at-death in years									Adults of unknown age
	Neonate	0–4	5–9	10–14	15–19	20–29	30–39	40–49	50+	
Number of individuals	3	18	7	1	11	21	22	8	6	27

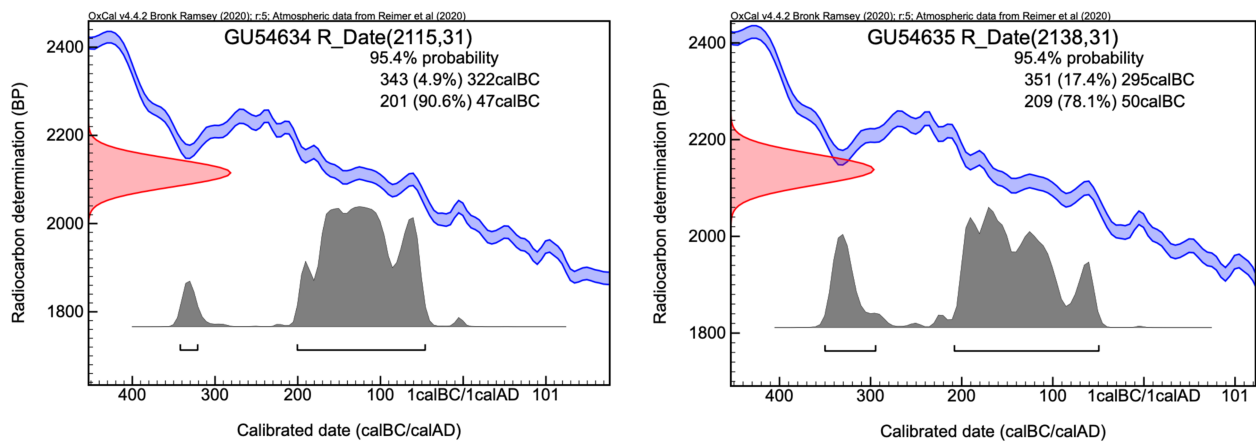


FIGURE 3 Calibrated radiocarbon date curves for (a) H-12 (GU54634) and (b) H-1 (GU54635) [Colour figure can be viewed at wileyonlinelibrary.com]

TABLE 2 Information for radiocarbon dating determination

Individual number	SUERC lab. No.	Skeletal element(s)	$\delta^{13}\text{C}$ relative to VPDB	$\delta^{15}\text{N}$ relative to air	C/N ratio	Radiocarbon age (BP)	68.2% HPD range	95.4% HPD range	Adjusted date range
H-12	GU54634	Tooth (maxillary canine)	-18.1	10.0	3.2	2,115 ± 31	172–56 cal BCE	343–47 cal BCE	293 BCE–03 cal CE
H-1	GU54635	Tooth (mandibular premolar)	-18.8	9.7	3.0	2,138 ± 31	340–106 cal BCE	351–50 cal BCE	331–30 cal BCE

TABLE 3 Type of skeletal trauma observed on the crania and associated evidence of decapitation

Individual number	Age	Sex	Sharp-force trauma to cranium	Blunt-force trauma to cranium	Peri-mortem fractures to cranium	Maxillofacial trauma	Dental trauma	Evidence of decapitation
Sk. 5	Middle/mature adult	Male	0	X	X	X	0	X
Sk. 32	Adult	Male	0	X	X	0	0	X
Sk. 34	Young adult	Unobservable	0	X	X	X	X	X
Sk. 52	Young adult	Male	0	X	X	X	X	X
Sk. 64	Adult	Probable male	X	X ^a	X	X	0	-
Sk. 76	Young adult	Unobservable	X	X	X	-	-	-
Sk. 87	Young adult	Probable female	0	X	X	0	-	X
H-12	Old adult	Male	X	X ^a	X	0	0	0

Note: X = present; 0 = absent; - = unobservable.

^aOccurred ante-mortem.

331–30 cal BCE, and H-12 was adjusted by 50 years to 293 BCE–03 cal CE (Table 2).

The archeological finds from layer III suggest a narrower date range than provided by the radiocarbon dates. Given the presence of Roman military paraphernalia located on top of the remains in layer II, it is likely that the skeletal remains under investigation from layer III pre-date the Roman invasion in 63 BCE. Although it is possible (based on the ceramic assemblage) that the remains could date as late as the late 1st century BCE, it is more likely that the remains date to the late 2nd century–early 1st century BCE.

3 | RESULTS

3.1 | Cranial trauma

Peri-mortem sharp-force trauma was identified on the posterior aspect of the crania of three individuals (Sk. 64, Sk. 76, and H-12) (Table 3). Two sharp-force injuries as well as extensive peri-mortem fractures were observed on the right and left parietal bones of Sk. 64, indicating that this individual was struck multiple times (Figure 4). Both of these injuries were caused by a bladed weapon,




FIGURE 4 (a) Two peri-mortem sharp-force injuries located on the posterior aspect of the right and left parietal bone of an adult individual (Sk. 64); (b) detail of superficial blade trauma (indicated by arrow) located on the posterior aspect of the right parietal; (c) SEM micrograph ($\times 30$) of the traumatic injury located on the posterior aspect of the right parietal (from black rectangle in 4b). Image credit: J. M. Dittmar [Colour figure can be viewed at wileyonlinelibrary.com]

likely a sword, as indicated by the smooth injury margins, fine striae and the “V”-shaped incision of a superficial wound found on the cranium (Figure 4c). Sk. 76 has a penetrating sharp-force injury located on the occipital bone along the axial plane, approximately 2 cm superior to the external occipital protuberance. We could not determine the full extent of this injury due to extensive peri-mortem fractures which resulted in the complete fragmentation of the posterior aspect of the cranial vault. The sharp-force injuries observed on Sk. 64 and Sk. 76 would have been fatal; however, it is not possible to state the exact cause of death because of the fragmentation of the skeletal remains and the lack of soft tissue. The sharp-force injury located on the occipital bone of H-12 (Figure 5) does not penetrate the skull and was likely not the cause of death. However, this does not necessarily mean that this injury did not contribute to this individuals' death. The location and morphology of the weapon injuries observed indicate that these individuals were struck while they were facing away from their assailant(s).

Evidence of peri-mortem blunt-force trauma was identified on all eight crania. The damage to each is extensive, and it was not possible to reconstruct the full extent of the injuries that each individual sustained. Sk. 32 had numerous peri-mortem fractures on the cranial vault including a hinge fracture located in the approximate center of the occipital bone, along the axial plane. It is evident that this individual was struck in the back of the head with a blunt object. Given the extent of the peri-mortem fractures observed, it is likely that the observed injuries were caused by numerous blows to the head. Sk. 5 also has substantial peri-mortem damage to the skull that is concentrated on the right parietal and temporal bone. The extensive

peri-mortem fractures to this skull were likely caused by at least one blow to the right side of the head. Sk. 34, Sk. 52, and Sk. 87 likely suffered multiple traumatic injuries. Each of these crania was shattered peri-mortem, and it was not possible to determine the origin of the force(s) that caused these skulls to fragment in this way.

Two individuals with sharp-force trauma to the cranium also had ante-mortem depressed fractures present on the cranial vault. The observed depressed fractures only affected the outer table, with no evidence of radiating fractures. H-12 had two ante-mortem depressed fractures located on the frontal bone. The smaller of the two depressions (1.2 cm at the widest point) is oval in shape and is located on the right aspect of the frontal bone, approximately 2.5 cm superior from the midpoint of the right orbital margin. The second, larger depressed fracture (1.6 cm \times 1.1 cm) is semioval in shape and is located on the midline of the frontal bone, approximately 3.5 cm inferior to bregma. Sk. 64 also had two ante-mortem depressed fractures on the cranial vault; one located on the posterior aspect of the right parietal and the other located on the posterior of the left parietal. The depressed fracture located on the right parietal is circular (approximately 1 cm in diameter) and is located within 1 cm to the right of the sagittal suture, and approximately 3 cm superior to lambda. The depressed fracture located on the posterior of the left parietal is circular in shape (approximately 2.5 cm in diameter) and is located 5.5 cm to the left of the sagittal suture. Although depression fractures to the cranium can be accidental, Guyomarc'h et al. (2010) found that depressed fractures are more often caused by a blow to the head, while fractures from falls were more likely to be linear or radial. However, depressed fractures that result from blows are larger

on average than those observed here (see Guyomarc'h et al., 2010). This suggests that the depressed fractures observed on these individuals are more likely to be accidental in nature, but it is not possible to rule out interpersonal violence as a potential cause.

3.2 | Maxillofacial and dental trauma

Ten individuals that had at least one facial bone present had evidence of peri-mortem maxillofacial trauma. The majority of the trauma

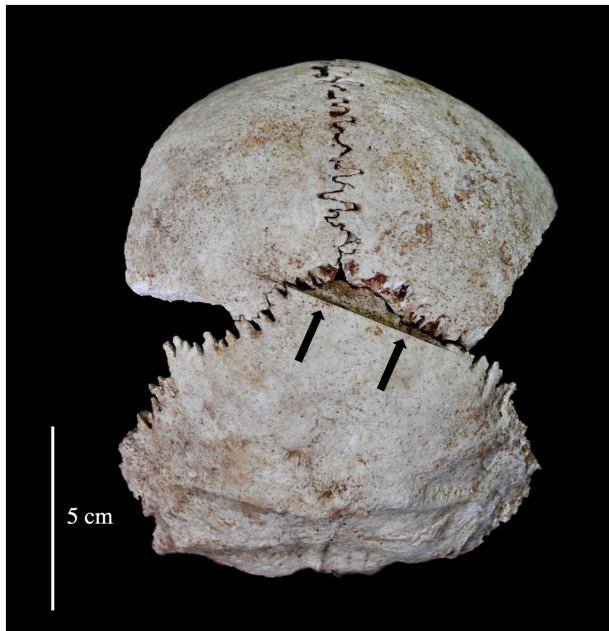

FIGURE 5 Peri-mortem sharp-force trauma (indicated by arrows) located on the superior aspect of the occipital bone and the posterosuperior aspect of the left parietal bone of an adult male (H-12). Image credit: J. M. Dittmar [Colour figure can be viewed at [wileyonlinelibrary.com](https://onlinelibrary.wiley.com)]

observed on the facial bones was blunt-force in nature, but three individuals had sharp-force injuries to the mandible (discussed below). Substantial, potentially fatal peri-mortem damage was observed on multiple individuals, including H-12, an adult male that had extensive peri-mortem fractures to multiple facial elements. These included a maxilla fracture that extended through the anterolateral margins of the nasal fossa and through the inferior wall of the maxillary sinus (Le Fort type I fracture). The anterior nasal spine of this individual has completely fractured and has been lost. This pattern of fractures indicates that this individual likely experienced a blow directed at the midface from straight on (Le Fort & Tessier, 1972; Phillips & Turco, 2017).

Of the 10 mandibles analyzed, seven had multiple peri-mortem fractures, which were the result of blunt-force trauma (see Table 4). The most frequently observed fracture location was the body of the mandible ($n = 8$), followed by the mandibular condyles ($n=6$). Fractures to the body of the mandible, as well as those to the mandibular condyles are most commonly caused by direct trauma from interpersonal violence (King et al., 2004; Silvennoinen et al. 1992). Of those with fractured mandibular condyles, two individuals (H-12 and Sk. 19) had condylar head fractures, and four individuals had subcondylar fractures. Fractures to the coronoid process on the mandible were observed in three individuals (H-12, Sk. 19, and Sk. 87). This type of fracture can occur from localized force to the zygomatic arch and is commonly associated with other maxillofacial fractures (Boffano et al., 2014). Indeed, fractured zygomatic arches were observed in both of these individuals. The comparatively high number of mandibular fractures suffered by each individual may reflect the brutal nature of the force used by the assailant(s), as higher numbers of mandibular fractures have been reported from domestic violence than other etiologies (Anyanechi, 2010).

In addition to this, three individuals (MH-08, Sk. 19, and Sk. 52) had evidence of peri-mortem sharp-force trauma to the mandible as well as peri-mortem radiating fractures that resulted from the impact. The injuries on MH-08 indicate that this adult male was struck in

TABLE 4 Anatomical location of peri-mortem fractures on the mandible for each individual

Individual no.	Symphysis	Alveolar process	Body		Angle		Ramus		Condyle		Coronoid process	
			R	L	R	L	R	L	R	L	R	L
5	0	X	0	X	0	X	0	0	0	X	0	0
MH-07	X	X	X	X	-	-	-	-	-	-	-	-
MH-08	X ^a	-	X ^a	X ^a	-	-	-	-	-	-	-	-
17	X	X	0	0	0	0	X	0	0	X	-	0
19	0	X	0	X	0	-	X ^a	-	X	-	X	-
34	0	X	X	X	0	-	0	-	X	-	-	-
52	0	X	X ^a	0	0	-	0	-	X	-	0	-
64	-	X	-	X	-	0	-	0	-	0	-	0
87	-	0	X	-	0	-	0	-	0	-	X	-
H-12	0	-	0	0	X	X	0	0	X	X	X	X

Note: X = fracture present; 0 = fracture not present; - = unobservable.

^aSecondary to sharp force trauma.

the face with a bladed weapon; the force of the blow caused the mandible to completely fracture along the axial plane. The sharp-force injuries on the inferior aspect of the body of the mandible of Sk. 52 progressed from posterior to anterior and likely occurred as the result of a decapitation where the blade progressed through the neck and terminated in the body of the mandible (Figure 6a). The position and termination point of the sharp-force injury on Sk. 19 indicate that the blade progressed inferior to superior (Figure 6b). This injury may represent an attempt at decapitation that occurred from the front while the neck was extended.

Dental trauma, injuries that occur to the teeth and/or to the surrounding alveolar bone, was identified on seven of the individuals examined. The type of the traumatic dental injuries reported here is consistent with violent interpersonal combat (Lukacs, 2007) but can also occur as the result of a fall (Lam et al., 2008).

In this assemblage, the blunt-force damage to the maxillofacial bones could potentially have been the result of blow(s) to the face, a peri-mortem fall where the individuals were unable to prevent themselves from falling onto their face or from the post-mortem deposition process that consisted of boulders being thrown on top of the remains after the bodies were deposited into the cistern. Although it is highly likely that at least some of the peri-mortem fractures to the maxillofacial area are the result of violence during life, it is not possible to completely rule out that the observed damage was inflicted as a result of the post-mortem treatment.

3.3 | Trauma to post-cranial elements

The post-cranial elements analyzed consisted primarily of vertebrae ($n = 31$). A total of 17 vertebra from 16 individuals had peri-mortem

sharp-force trauma. In addition to this, a right first rib from individual Sk. 34 and a disarticulated fragment of the proximal shaft of a right femur were also analyzed. No evidence of skeletal trauma was identified on the first rib fragment, though sharp-force trauma indicative of decapitation was found on one vertebra from this individual. The femur fragment had peri-mortem sharp-force trauma as well as a peri-mortem fracture. The orientation of the injury indicates that the blade progressed inferolateral to superomedial. The blade did not completely sever the shaft but was wielded with substantial force which resulted in the bone completely fracturing as evidenced by a large breakaway spur on the anterior aspect of the shaft.

3.3.1 | Evidence of decapitation

Fifteen individuals had peri-mortem sharp-force trauma to vertebrae that is consistent with decapitation; one additional individual had sharp-force trauma that indicates that decapitation was attempted but not successfully completed (i.e., the head was not completely severed) (Table 5). Evidence of decapitation was also observed on the mandible from Sk. 52, and a possible attempt at decapitation was observed on the mandible of Sk.19 (see Figure 6).

Every attempt was made to identify the specific vertebra affected. When this was not possible due to damage, or if the vertebra was isolated, the vertebra was classed as a mid-cervical vertebra (C3–C5) or as a lower cervical vertebra (C6–C7). Evidence of decapitation was most commonly identified on mid-cervical vertebrae (C3–C5). Vertebrae from two individuals (Sk. 32 and Sk. 87) had multiple sharp-force injuries that indicate that numerous attempts were made to decapitate these individuals. Sk. 32 had two sharp-force injuries located on two sequential mid cervical vertebrae, and the fifth

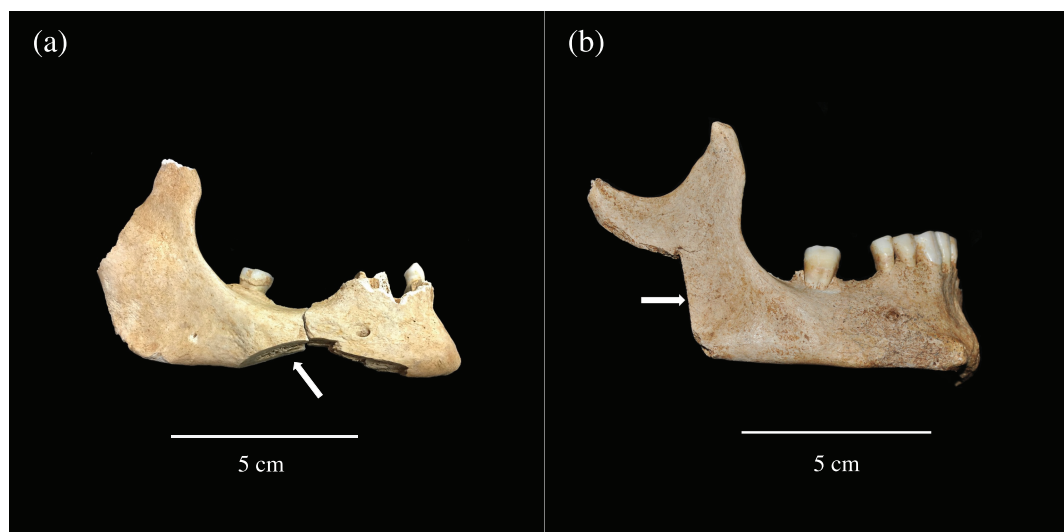


FIGURE 6 (a) Peri-mortem sharp-force trauma (indicated by arrow) located on the inferior aspect of the body of the mandible indicative of decapitation if neck in neutral alignment (Sk. 52); (b) peri-mortem sharp-force trauma (indicated by arrow) and radiating fractures located on the mandibular ramus that may represent an attempt at decapitation if neck was extended (Sk. 19). Image credit: J. M. Dittmar [Colour figure can be viewed at wileyonlinelibrary.com]

TABLE 5 Location and description of trauma on vertebrae

Individual number	Element(s) present	Location of sharp-force trauma	Evidence of successful or attempted decapitation	Description of origin and progression (if discernable)
MH-01	Mid cervical vertebra	Inferior aspect of vertebral body	Yes (successful)	Vertebral body has been completely severed. Progression of blade is likely posterior to anterior based on the presence of a breakaway spur and chipping on the anterior aspect of the vertebral body.
MH-02	Mid cervical vertebra	Inferior aspect of vertebral body and inferior left facet	Yes (successful)	Vertebral body has been completely severed through the inferior aspect. The blade passed through the vertebra at an approximate 30° angle in relation to the axial plane (when viewing the individual from the front). Radiating fractures were observed on the inferior aspect of the left pedicle. The progression of the blade was likely anterior to posterior based on the location of perimortem fractures and breakaway notch on the laminae.
MH-03	Mid cervical vertebra	Superior aspect of left neural arch and left pedicle	Yes (successful)	Left superior articular facet has been severed. Not possible to determine origin or progression of blade.
MH-04	Mid cervical vertebra	Superior aspect of vertebral body	Yes (successful)	Vertebral body has been completely severed. The blade passed through the vertebra at an approximate 40° angle in relation to the axial plane. There are perimortem fractures through the pedicles, but it is not possible to determine origin or progression of blade.
MH-05	Mid cervical vertebra	Inferior aspect of vertebral body	Yes (successful)	Vertebral body has been completely severed. Not possible to determine origin or progression of blade.
MH-06	C1, C2 and a mid-cervical vertebra ^a	Inferior aspect of vertebral body of the mid-cervical vertebra	Yes (successful)	Vertebral body has been completely severed. The blade passed through the vertebra at an approximate 45° angle in relation to the axial plane. Given this angle, it is likely that the vertebra located inferiorly would have also been affected. Blade progressed anterior to posterior of body.
MH-07	Lower cervical vertebra	Inferior aspect of vertebral body	Yes (successful)	Vertebral body has been completely severed, and radiating fractures are present on the right pedicle. The blade likely originated on the individuals' right side and progressed to the posterior aspect of the left side along the inferior aspect of the vertebral body, at an approximate 40° angle. It is likely that the inferior vertebra would have also been affected.
MH-08	Lower cervical vertebra	Inferior aspect of vertebral body	Yes (successful)	Vertebral body has been completely severed. Blade progression was from anterior to posterior, with the entry point located on the individuals' right side.

(Continues)

TABLE 5 (Continued)

Individual number	Element(s) present	Location of sharp-force trauma	Evidence of successful or attempted decapitation	Description of origin and progression (if discernable)
MH-09	Mid cervical vertebra	Inferior aspect of vertebral body	Possible attempt at decapitation	The anteroinferior portion (comprising approximately 25%) of the vertebral body has been severed. The blade progressed from anterosuperior to posteroinferior through the anterior half of the vertebral body. The neural arch was unaffected. The head would not have been severed as a result of this blow.
MH-10	Mid cervical vertebra	Center of the vertebral body	Yes (successful)	Vertebral body has been completely severed mid-body. Unable to determine origin or progression of blade.
MH-11	Lower cervical vertebra	Superior aspect of vertebral body and both superior articular facets	Yes (successful)	Vertebral body and both superior articular facets have been completely severed. Blade progression was likely posterior to anterior.
MH-12	Mid cervical vertebra	Inferior aspect of vertebral body, through both inferior articular facets	Yes (successful)	Vertebral body has been completely severed. Blade likely entered the right side of the vertebra and progressed transversely and slightly inferiorly through the vertebral column.
Sk. 5	C1, C2, C4, C5	The vertebral body of C5	Yes (successful)	Vertebral body has been completely severed. Not possible to determine origin or progression of blade.
Sk. 32	Two mid cervical vertebrae ^b	Inferior aspect of the vertebral body of the superior cervical vertebra; superior aspect of the vertebral body of the inferior vertebra	Yes (both attempted and successful)	Two separate strikes at slightly different angles. The angles and position of these two injuries indicates that they could not have been caused by the same strike. On the superior vertebra, the anteroinferior portion (comprising approximately 25%) of the vertebral body has been severed at an approximate 15° angle in relation to the axial plane (when viewing the individual's front). The right inferior facet was fractured (peri-mortem) which suggests that the blade may have entered through the individual's right side, progressed from anterosuperior to posteroinferior through the inferior portion of the vertebral body but terminated before reaching the spinous process. On the inferior vertebra, the right superior facet and the superior aspect of the vertebral body on the right side have been severed. The orientation of the injury suggests that the blade may have entered through the individual's right side, progressed through the right superior facet and

TABLE 5 (Continued)

Individual number	Element(s) present	Location of sharp-force trauma	Evidence of successful or attempted decapitation	Description of origin and progression (if discernable)
Sk. 34	Mid cervical vertebra	Inferior aspect of vertebral body and inferior right articular facet	Yes (successful)	approximately half of the superior aspect of the vertebral body. The head would not have been severed as a result of this blow. Vertebral body and the inferior right articular facet have been severed. Not possible to determine origin or progression of blade.
Sk. 87	C1–C5	Multiple injuries to the vertebral body of C5	Yes (both attempted and successful)	Three injuries present on C5. Blade progression in two of these strikes was anterior to posterior and the third strike entered the left superior aspect of the vertebral body and progressed inferiorly.

^aThe mid cervical vertebra does not articulate with C2.

^bThese vertebrae articulate.




FIGURE 7 Multiple sharp-force injuries to lateral aspect of a cervical vertebra that indicate repeated attempts at decapitation (Sk. 87), highlighted on right-hand image. Image credit: J. M. Dittmar [Colour figure can be viewed at [wileyonlinelibrary.com](https://onlinelibrary.wiley.com/doi/10.1002/oa.3084)]

cervical vertebra of Sk. 87 had three different sharp-force injuries (Table 5; Figure 7).

4 | DISCUSSION

Numerous sharp-force injuries and peri-mortem fractures were observed on the subset of skeletal remains that could be retained for further study. The damage to the maxillofacial bones is consistent with blunt-force trauma that was sustained by a blow or multiple blows to the face with a blunt object, or by the face colliding with an immobile object. The locations of sword injuries to the head indicate that some of these individuals were attacked while they were facing away from their assailant(s), potentially while fleeing from them. At least 16 individuals were decapitated, two of whom had evidence of multiple sharp-force injuries to the same vertebra (Table 5; Figure 7). This could indicate that these individuals were held stationary while being decapitated or that these individuals were already dead when they were decapitated.

The interpretation of this skeletal assemblage was marred by the constraints of the excavation and the conditions under which the initial assessment of the skeletal remains took place; we acknowledge that there are several limitations of this study (which are described in further detail below). The most problematic of these was our inability to analyze all of the skeletal remains recovered from the cistern. As such, it was not possible to determine how many of the individuals in the cistern had skeletal trauma. However, the bodies of these individuals were disposed of in a manner that is inconsistent with accepted burial practices for 2nd–1st century BCE Jerusalem (Abadi & Regev, 2020; Hachlili, 1980), and the non-normative burial treatment of these individuals cannot be ignored when attempting to interpret the skeletal assemblage. The demographics of the individuals recovered from the cistern show that neonates, infants, children, and adult men and women were all haphazardly deposited within the cistern over a relatively short period of time. The positions of the semi-articulated skeletons suggest that the bodies, or portions of bodies, were thrown in rather than positioned with care. The individuals with skeletal trauma were intermingled with those that could not be

properly assessed for evidence of skeletal trauma indicating deposition was contemporaneous. Although skeletal trauma could not be recorded on all individuals within this context, it is highly likely that all of the individuals that were disposed of in the cistern died around the same time, most likely following the event that resulted in the violent death and mutilation of at least 23 individuals. Given the demographics of the individuals with evidence of lethal injuries, which include both males and females, it is unlikely that this assemblage consists of those that died while actively participating in a battle. The lethal nature of the injuries on those individuals that could be retained for study, coupled with the fact that individuals of all ages were unceremoniously deposited together into the cistern (see Table 1), suggests that these individuals may have been the victims of a mass murder or a massacre.

Although several scholars have worked on refining the definitions of terms that describe different types of mass atrocities (e.g., massacre, mass killing, and genocide), there is still substantial discontinuity in how these terms are used colloquially and within different academic disciplines (see Dwyer & Ryan, 2012: pp. xi–xvi; Mullen, 2004; Semelin, 2003, 2007). Within this work, a “mass murder” is defined as the intentional killing of multiple people (three or more) in a single event over a specific period of time (e.g. 24 hours) by one person, group of people, or an organization (Dietz, 1986; Duwe, 2004; Fox & Levin, 2003). Some scholars have added additional criteria to this definition including the location at which the murders occurred and the geographical distance between murders (Holmes & Holmes, 1998). However, highly specific definitions have been deemed “unduly arbitrary” or are operationally problematic (Duwe, 2007, p. 15) and can further limit historic examinations of such events. A massacre is defined as an event where a large number of people are indiscriminately killed by one or more assailant(s) where the victims are unable to defend themselves (i.e., civilians) (Semelin, 2007, p. 4). For the purposes of this work, the term “civilian” has been modified from the definition used by Adhikari (2019) and refers to unarmed individuals that were not part of a formal or an informal fighting force, including the military, insurrectionary forces, or militia.

The main difference between these acts is the motivation behind the killing. According to Fox and Levin (2003), “mass murder” is most commonly internally motivated. Such motivations can include a personal agenda or psychopathology (Mullen, 2004), but a study by Taylor (2018) found that those that committed mass murders (in modern times) had a range of motivations including: relationship issues, mental health issues, criminal motivation, emotional triggers, and financial issues. The majority of the perpetrators were “triggered” by a specific event, with the most commonly reported reason being “a relationship issue” (Taylor, 2018).

Massacres, on the other hand, are one-sided, public displays with a strong performative aspect where violence is not directed at an individual, but at a group that has symbolic significance (Redfern, 2017; Schmidt & Schröder, 2001; Whitehead, 2004). The lack of emphasis placed on the individual distinguishes a massacre from other acts of violence such as murder, where the act is directed at a specific individual (Dwyer & Ryan, 2012). Purposeful disfigurement and mutilation of

the victims, who are “othered” by the attacking group, are also common during a massacre. Such displays often include torture, bodily mutilation, dismembering, and burning the bodies after death. The destruction of the body symbolically communicates the destruction of the victim's individual identities, but also the identity of the group. Through this process, the perpetrators experience a heightened sense of identity with the others in their group (Dwyer & Ryan, 2012).

Evidence of bodily dismemberment (i.e., decapitation) identified on these remains indicates that these individuals were “othered” and dehumanized by the perpetrators. This, along with the number ($n = 124$) and the ages and sexes of victims deposited into the cistern, suggests that these individuals were indiscriminately killed and were thus the victims of a massacre, rather than a mass murder. Bar-Kochva (2019) has previously suggested that these remains could be from Ptolemy IX Lathyrus's conquest of Judea in 103 BCE. Specifically, it was argued that this assemblage may have been the result of cannibalism by soldiers during the campaign (Bar-Kochva, 2019, pp. 51–57). This interpretation, refuted by the excavators of the site (Lieberman et al., 2020), is not supported by this assessment of the skeletal trauma. There is no osteological evidence, such as tooth marks or knife marks, to suggest that cannibalism was practiced.

The collective witnessing of displays of violence has a powerful effect on the survivors. Highly visible acts of violence such as massacres are incorporated into a society's collective memory and thus can be used as a mechanism for the creation of social control of one group by another more dominant group (Whitehead, 2004). Klusemann (2012) suggests that all massacres are preceded by political, economic, and cultural events that shape the ideas of the perpetrators that a massacre would solve a perceived problem. In general, massacres fall into two major categories: those that are to facilitate the manipulation of power and those to maintain the balance of power between one group and another (Semelin, 2001). When this event is considered within the historical context, it is likely that the individuals in the water cistern represent archeological evidence of an attack sanctioned by a Hasmonean king, possibly Alexander Jannaeus, against elements of the civilian population of Jerusalem in order to maintain social control.

4.1 | The Hasmonean Era: Performative violence and social control

The reign of Alexander Jannaeus (103–76 BCE) was a seminal period in Hellenistic Judea that was characterized by internal and external conflict and has been described as “oppressive” and “perpetually at war” (Salarini, 2001; Wilker, 2018). In *Antiquities* (Books XIII–XIV), Josephus describes how a crowd revolted against Jannaeus during a Festival of Tabernacles (Josephus, 2009a). They accused him of being unworthy of the high priesthood because of his descent and pelted him with citrons and wands made of palm branches (Josephus, 2009a, aj. 13.372–383). In response, Jannaeus reportedly slaughtered 6,000 protesters (Josephus, 2009a, aj. 13.373; Babota, 2020). The growing resentment between Jannaeus and the Pharisees led to a 6-year long

civil war during which those that opposed the legitimacy of the Hasmonean leadership suffered heavy losses at the hands of a mercenary-heavy army (Josephus, 2009a, bj. 13.372–374, 376).

The conflict between Jannaeus and the Pharisees culminated with the invited military invasion of the Seleucid King Demetrius III Eukerus (97/96–88/87 BCE) against Jannaeus in 88 BCE (Dąbrowa, 2011; Josephus, 2009a, 13.376–377). In retribution for their betrayal, Jannaeus reportedly crucified “eight hundred” of those who defected to aid Demetrius III (Josephus, 2009a, 13.380; Josephus, 2009b, 1.97). A passage in Peshar on Nahum (Dead Sea Scrolls: 4Q169) describes the mass slaughter of the Pharisees who invited Demetrius III to conquer Judea (Lieberman et al., 2020). This passage gives details of how Jannaeus watched the massacre of their families. Although it is not possible to be certain if the skeletal remains of the individuals in the cistern resulted from one of the specific historical events described here, the characteristics of the trauma observed may provide physical evidence that violence was used as mechanism to legitimize the Hasmonean kingdom and to maintain social control.

4.2 | Limitations of the study

In addition to our inability to analyze all of the skeletal remains recovered from the cistern, there were several other limitations that have impacted this study and the conclusions that were able to be drawn. As previously outlined in the methods section, the skeletal remains could not be washed in the field prior to assessment, nor could the skeletal material be fully laid out to be recorded. Given the time constraints of the initial assessment of the skeletal remains, it was also not possible to try to re-unite skeletal elements that had become disarticulated post-mortem, either through the deposition process or as the result of decomposition. As a result of these factors, age and biological sex remain unknown for many of the individuals that were deposited into the cistern. It is also probable that evidence of skeletal trauma on other individuals was obscured by soil and thus not recorded during the initial assessment. The injuries reported here likely represent a subset of the full range of skeletal injuries that were actually present. This is further compounded by the impossibility to determine the extent of injuries to soft tissues that may have been present in other individuals in the mass grave.

The assessment of injuries sustained through blunt-force trauma was complicated by the post-mortem treatment of the bodies. Unfortunately, it was not always possible to distinguish between peri-mortem blunt-force trauma sustained during the violent encounter from post-mortem damage that occurred when the bodies were placed into the cistern or when the layer of rocks were dropped on top of the bodies to seal the mass grave.

5 | CONCLUSION

The skeletal assemblage from the Russian Compound represents the largest collection of violence-inflicted casualties ever found in Israel.

Prior to this, relatively few examples of lethal trauma to the cranium have been identified in this region of the eastern Mediterranean, dating to the Hellenistic (see Goldstein et al., 1981), Roman (Nagar, 2003, pp. 127–130), and medieval periods (Mikulski et al., 2021; Mitchell et al., 2006), although numerous other examples have been identified in historical textual sources (Mitchell, 2004, pp. 124–136). Within the sample of skeletal material that could be analyzed, numerous peri-mortem sharp-force injuries were observed including lethal injuries to the cranium, maxillofacial bones, and cervical vertebrae. The location of the sharp-force trauma on the posterior of three crania indicates that some individuals were attacked while they were facing away from their assailant(s), possibly while fleeing from them. In addition to this, at least 16 individuals were decapitated. Several other individuals had extensive peri-mortem damage to their dentition and maxillofacial bones that is consistent with blunt-force trauma that could have been the result of a blow, or multiple blows to the face, but could have also been sustained as the result of the post-mortem treatment of the body.

The lethal injuries and evidence of bodily mutilation observed on the subset of individuals analyzed, in addition to their haphazard deposition into the cistern, indicate that these individuals were the victims of a massacre. Although the remainder of the individuals in the cistern could not be examined properly, the haphazard deposition of the bodies as well as the demographics (i.e., age and sex) of the complete skeletal assemblage provides supporting evidence that everyone deposited into the cistern was possibly a victim of the same mass atrocity. When placed within the historical context, it is possible this skeletal assemblage is evidence of a large-scale massacre following one of the uprisings during the reign of the Hasmonean king Alexander Jannaeus during the end of the 2nd century to early 1st century BCE. While it is not possible to pinpoint the exact encounter during which these individuals were killed, the skeletal trauma presented here is possibly the first direct archeological evidence for the use of socially sanctioned violence to maintain social control and legitimize the Hasmonean state.

ACKNOWLEDGMENTS

Partial funding for JD to complete this research was provided by Darwin College, University of Cambridge. The authors would like to thank Craig Cessford of the Cambridge Archaeological Unit for his assistance with the radiocarbon dates, David Errickson of Cranfield University for aiding in the analysis of the tool marks, and the reviewers for their comments on this manuscript. The excavation was carried out by the Israel Antiquities Authority (Permit number A7929) and supported by the Bezalel Academy of Art and Design.

CONFLICT OF INTEREST

None.

DATA AVAILABILITY STATEMENT

The data that support the findings of this study are available from the corresponding author upon reasonable request.

ORCID

Jenna M. Dittmar  <https://orcid.org/0000-0003-3514-1869>

Yossi Nagar  <https://orcid.org/0000-0003-0139-6492>

Piers D. Mitchell  <https://orcid.org/0000-0002-1009-697X>

REFERENCES

- Abadi, O. Y., & Regev, E. (2020). Folded wheel-made oil lamps, standing pit burial caves and Judaeen ethnic identity in the Hasmonean period. *Palestine Exploration Quarterly*, 152(3), 248–272. <https://doi.org/10.1080/00310328.2020.1750252>
- Adhikari, M. (2019). 'No savage shall inherit the land': Civilian-driven violence in the making of settler genocides. In M. Adhikari (Ed.), *Civilian-driven violence and the genocide of indigenous peoples in settler societies* (pp. 1–30). Routledge. <https://doi.org/10.4324/9781003015550-1>
- Alunni-Perret, V., Muller-Bolla, M., Laugier, J. P., Lupi-Pégurier, L., Bertrand, M. F., Staccini, P., Bolla, M., & Quatrehomme, G. (2005). Scanning electron microscopy analysis of experimental bone hacking trauma. *Journal of Forensic Sciences*, 50(4), 796–801. <https://doi.org/10.1520/JFS2003213>
- Anyanechi, C. E. (2010). Mandibular fractures associated with domestic violence in Calabar, Nigeria. *Ghana Medical Journal*, 44(4), 155–158. <https://doi.org/10.4314/gmj.v44i4.68909>
- Arbiv, K., Nagar, Y., & Lieberman, T. (2018). The 'Lion of Wrath' and legionary burials: Evidence of a mass-burial in the Russian Compound. In J. Uziel, et al. (Eds.), *New studies in the archaeology of Jerusalem and its region* (pp. 100–114). IAA.
- Atkinson, K. (2016). *A history of the Hasmonean state: Josephus and beyond*. T&T Clark.
- Babota, V. (2020). Alexander Janneus as high priest and king: Struggling between Jewish and Hellenistic concepts of rule. *Religions*, 11, 40. <https://doi.org/10.3390/rel11010040>
- Bar-Kochva, B. (2019). On the history of the Judean Desert sect: The relations with the rulers of the Hasmonean state from Simon to Jannaeus (143–76 BCE). *Zion*, 84, 5–58.
- Bar-Nathan, R. (2002). *Hasmonean and Herodian palaces at Jericho: Final reports of the 1973–1987 excavations*, Vol. III: *The pottery*. Israel Exploration Society.
- Boffano, P., Kommers, S. C., Rocchia, F., Gallesio, C., & Forouzanfar, T. (2014). Fractures of the mandibular coronoid process: A two centres study. *Journal of Cranio-Maxillofacial Surgery*, 42, 1352–1355. <https://doi.org/10.1016/j.jcms.2014.03.025>
- Bronk Ramsey, C. (2009). Bayesian analysis of radiocarbon dates. *Radiocarbon*, 51, 337–630. <https://doi.org/10.1017/S0033822200033865>
- Bronk Ramsey, C., & Lee, S. (2013). Recent and planned developments of the program OxCal. *Radiocarbon*, 55, 720–730. <https://doi.org/10.1017/S0033822200057878>
- Dąbrowa, E. (2011). Demetrius III in Judea. *Electrum. Studia z Historii Starożytnej*, 18, 175–182.
- Dietz, P. (1986). Mass, serial and sensational homicides. *Bulletin of the new York Academy of Medicine*, 62, 477–491.
- Dittmar, J. M., Errickson, D., & Caffell, A. (2015). A comparison of silicone casting materials for archaeological applications. *Journal of Archaeological Science: Reports*, 4, 559–564. <https://doi.org/10.1016/j.jasrep.2015.10.008>
- Dunbar, E., Cook, G. T., Naysmith, P., Tripney, B. G., & Xu, S. (2016). AMS ¹⁴C dating at the Scottish universities environmental research Centre (SUERC) radiocarbon dating laboratory. *Radiocarbon*, 58, 9–23. <https://doi.org/10.1017/RDC.2015.2>
- Duwe, G. (2004). The patterns and prevalence of mass murder in twentieth century America. *Justice Quarterly*, 21(4), 729–761. <https://doi.org/10.1080/07418820400095971>
- Duwe, G. (2007). *Mass murder in the United States: A history*. McFarland & Company Inc.
- Dwyer, P., & Ryan, L. (2012). The massacre and history. In P. Dwyer & L. Ryan (Eds.), *Theatres of violence: Massacre, mass killing and atrocity throughout history* (pp. xi–xxv). Berghahn.
- Fox, G. L., Benson, M. L., DeMaris, A. A., & van Wyk, J. (2002). Economic distress and intimate violence: Testing family stress and resources theories. *Journal of Marriage and Family*, 64, 793–807. <https://doi.org/10.1111/j.1741-3737.2002.00793.x>
- Fox, J. A., & Levin, J. (2003). Mass murder: An analysis of extreme violence. *Journal of Applied Psychoanalytic Studies*, 5(1), 47–64. <https://doi.org/10.1023/A:1021051002020>
- Galloway, A., Zephro, L., & Wedel, V. (2014). Diagnostic criteria for the determination of timing and fracture mechanism. In V. Wedel & A. Galloway (Eds.), *Broken bones: Anthropological analysis of blunt force trauma* (2nd ed.) (pp. 47–58). Charles C. Thomas.
- Goldstein, M. S., Arensburg, B., & Nathan, H. (1981). Skeletal remains of Jews from the Hellenistic and Roman periods in Israel. *Bulletins et Mémoires de la Société d'Anthropologie de Paris*, 8, 11–24. <https://doi.org/10.3406/bmsap.1981.3807>
- Guyomarç'h, P., Campagna-Vaillancourt, M., Kremer, C., & Sauvageau, A. (2010). Discrimination of falls and blows in blunt force trauma: A multi-criteria approach. *Journal of Forensic Sciences*, 55, 423–427. <https://doi.org/10.1111/j.1556-4029.2009.01310.x>
- Hachlili, R. (1980). A second Temple period Jewish necropolis in Jericho. *The Biblical Archaeologist*, 43(4), 235–240. <https://doi.org/10.2307/3209798>
- Holmes, R. M., & Holmes, S. T. (1998). *Serial murder*. 2nd edn. Sage Publications, Inc.
- Josephus, F. (2009a). *The antiquities of the Jews*; translated by William Whiston. Ebook Available: <https://www.gutenberg.org/files/2848/2848-h/2848-h.htm>
- Josephus, F. (2009b). *The wars of the Jews or the history of the destruction of Jerusalem*; translated by William Whiston. Ebook Available: <https://www.gutenberg.org/files/2850/2850-h/2850-h.htm>
- King, R. E., Scianna, J. M., & Petruzzelli, G. J. (2004). Mandible fracture patterns: A suburban trauma center experience. *American Journal of Otolaryngology*, 25, 301–307. <https://doi.org/10.1016/j.amjoto.2004.03.001>
- Klusemann, S. (2012). Massacres as process: A micro-sociological theory of internal patterns of mass atrocities. *European Journal of Criminology*, 9, 468–480. <https://doi.org/10.1177/1477370812450825>
- Lam, R., Abbott, P., Lloyd, C., Lloyd, C., Kruger, E., & Tennant, M. (2008). Dental trauma in an Australian rural center. *Dental Traumatology*, 24, 663–670. <https://doi.org/10.1111/j.1600-9657.2008.00689.x>
- le Fort, R., & Tessier, D. P. (1972). Experimental study of fractures of the upper jaw. *Plastic and Reconstructive Surgery*, 50, 497–506. <https://doi.org/10.1097/00006534-197211000-00012>
- Lewis, J. E. (2008). Identifying sword marks on bone: Criteria for distinguishing between cut marks made by different classes of bladed weapons. *Journal of Archaeological Science*, 35, 2001–2008. <https://doi.org/10.1016/j.jas.2008.01.016>
- Lieberman, T., Arbiv, K., & Nagar, Y. (2020). The wrath of the lion: Evidence of a mass-burial in Hasmonean Jerusalem. *Tel Aviv*, 47, 89–107. <https://doi.org/10.1080/03344355.2020.1707448>
- Loe, L. (2017). Recording of interpersonal violent trauma. In P. D. Mitchell & M. Brickley (Eds.), *Updated guidelines to the standards for recording human remains* (pp. 49–51). Chartered Institute for Archaeologists/British Association for Biological Anthropology and Osteoarchaeology.
- Lukacs, J. R. (2007). Dental trauma and antemortem tooth loss in prehistoric canary islanders: Prevalence and contributing factors. *International Journal of Osteoarchaeology*, 17, 157–173. <https://doi.org/10.1002/oa.864>
- Mikulski, R. N. R., Schutkowski, H., Smith, M. J., Doumet-Serhal, C., & Mitchell, P. D. (2021). Weapon injuries in the crusader mass graves

- from a 13th century attack on the port city of Sidon (Lebanon). *PLoS ONE*, 16(8), e0256517. <https://doi.org/10.1371/journal.pone.0256517>
- Mitchell, P. D. (2004). *Medicine in the crusades: Warfare, wounds and the medieval surgeon*. Cambridge University Press.
- Mitchell, P. D., Nagar, Y., & Ellenblum, R. (2006). Weapon injuries in the 12th century crusader garrison of Vadum Iacob Castle, Galilee. *International Journal of Osteoarchaeology*, 16, 145–155. <https://doi.org/10.1002/oa.814>
- Moraitis, K., & Spiliopoulou, C. (2006). Identification and differential diagnosis of perimortem blunt force trauma in tubular long bones. *Forensic Science, Medicine and Pathology*, 2, 221–229. <https://doi.org/10.1385/FSMP:2:4:221>
- Mullen, P. E. (2004). The autogenic (self-generated) massacre. *Behavioral Sciences & the Law*, 22(3), 311–323. <https://doi.org/10.1002/bsl.564>
- Nagar, Y. (2002). Bone reburial in Israel—Legal restrictions and methodological implications. In C. Fforde, J. Hubert, & P. Turnball (Eds.), *The dead and their possessions: Repatriation in principle, policy and practice* (pp. 87–90). Routledge.
- Nagar, Y. (2003). *Who lived in Israel? A story of ancient populations*. Rakia.
- Phillips, B. J., & Turco, L. M. (2017). Le Fort fractures: A collective review. *Bulletin of Emergency & Trauma*, 5, 221–230. <https://doi.org/10.18869/acadpub.beat.5.4.499>
- Redfern, R. (2017). *Injury and trauma in bioarchaeology: Interpreting violence in past lives*. Cambridge University Press.
- Regev, E. (2013). *The Hasmoneans: Ideology, archaeology, identity* (Vol. 10). Vandenhoeck & Ruprecht.
- Reimer, P., Austin, W. E. N., Bard, E., Bayliss, A., Blackwell, P. G., Ramsey, C. B., Butzin, M., Cheng, H., Edwards, R. L., Friedrich, M., & Grootes, P. M. (2020). The IntCal20 northern hemisphere radiocarbon age calibration curve (0–55 cal kBP). *Radiocarbon*, 62, 725–757. <https://doi.org/10.1017/RDC.2020.41>
- Salarini, A. (2001). *Pharisees, scribes and Sadducees in Palestinian society: A sociological approach* (2nd ed.). William B. Eerdmans Publishing.
- Sampson, R. J., & Groves, W. B. (1989). Community structure and crime: Testing social-disorganization theory. *American Journal of Sociology*, 94, 774–802. <https://doi.org/10.1086/229068>
- Sauer, N. J. (1998). The timing of injuries and manner of death: distinguishing among antemortem, perimortem and postmortem trauma. In K. J. Reichs (Ed.), *Forensic osteology: Advances in the identification of human remains* (2nd ed.) (pp. 321–332). Charles C. Thomas.
- Schmidt, B., & Schröder, I. (2001). *Anthropology of violence and conflict*. Routledge.
- Scientific Working Group for Forensic Anthropology (SWGANTH). (2011). *Trauma analysis: Final report*. National Institute of Justice. Accessed: 6 August 2020. Available from: https://www.nist.gov/system/files/documents/2018/03/13/swganth_trauma.pdf
- Semelin, J. (2001). In consideration of massacres. *Journal of Genocide Research*, 3, 377–389. <https://doi.org/10.1080/14623520120097198>
- Semelin, J. (2003). Toward a vocabulary of massacre and genocide. *Journal of Genocide Research*, 5(2), 193–210.
- Semelin, J. (2007). *Purify and destroy: The political uses of massacre and genocide*. Columbia University Press.
- Silvennoinen, U., Iizuka, T., Lindqvist, C., & Oikarinen, K. (1992). Different patterns of condylar fractures: An analysis of 382 patients in a 3-year period. *Journal of Oral and Maxillofacial Surgery*, 50, 1032–1037. [https://doi.org/10.1016/0278-2391\(92\)90484-H](https://doi.org/10.1016/0278-2391(92)90484-H)
- Taylor, M. A. (2018). A comprehensive study of mass murder precipitants and motivations of offenders. *International Journal of Offender Therapy and Comparative Criminology*, 62(2), 427–449. <https://doi.org/10.1177/0306624X16646805>
- Tucker, B. K., Hutchinson, D. L., Gilliland, M. F., Charles, T. M., Daniel, H. J., & Wolfe, L. D. (2001). Microscopic characteristics of hacking trauma. *Journal of Forensic Sciences*, 46, 234–240. <https://doi.org/10.1520/JFS14955J>
- Ubelaker, D. H., & Adams, B. J. (1995). Differentiation of perimortem and postmortem trauma using taphonomic indicators. *Journal of Forensic Science*, 40, 509–512. <https://doi.org/10.1520/JFS13818J>
- Walker, P. L. (2001). A bioarchaeological perspective on the history of violence. *Annual Review of Anthropology*, 30, 573–596. <https://doi.org/10.1146/annurev.anthro.30.1.573>
- Whitehead, N. L. (2004). On the poetics of violence. In N. L. Whitehead (Ed.), *Violence* (pp. 55–77). School of American Research Press.
- Wilker, J. (2018). Between empires and peers: Hasmonean foreign policy under Alexander Jannaeus. *Electrum. Studia z Historii Starożytnej*, 25, 127–145. <https://doi.org/10.4467/20800909EL.18.007.8927>

How to cite this article: Dittmar, J. M., Nagar, Y., Arbiv, K., Lieberman, T., & Mitchell, P. D. (2022). Violence in Hasmonean Judea: Skeletal evidence of a massacre from 2nd–1st century BCE Jerusalem. *International Journal of Osteoarchaeology*, 32(4), 731–745. <https://doi.org/10.1002/oa.3084>