

SHORT COMMUNICATION

Hepatology

Histopathological findings from the investigation of paediatric acute hepatitis of unknown aetiology, United Kingdom 2022

Helen Callaby^{1,2} | Emma McGuire³ | Sanjay Rajwal⁴ | Jens Stahlschmidt⁵ | Jane Hartley⁶ | Rachel M. Brown⁷ | Maesha Deheragoda⁸ | Alberto Quaglia⁹ | Tommy Rampling¹ | Catherine F. Houlihan¹ | N. Claire Gordon¹ | Colin S. Brown^{3,10} | Ruth Simmons¹¹ | Anda Samson³ | Sema Mandal¹¹ | Tassos Grammatikopoulos^{12,13} | Alicia Demirjian^{3,14,15}

¹UKHSA Rare and Imported Pathogen Laboratory, Porton Down, London, UK

²Institute of Medical Sciences, University of Aberdeen, Aberdeen, UK

³HCAI, Fungal, AMR, AMU & Sepsis Division, UKHSA, London, UK

⁴Leeds Children's Hospital, Leeds, UK

⁵Department of Histopathology and Molecular Pathology, St James's University Hospital, Leeds Teaching Hospitals NHS Trust, Leeds, UK

⁶Liver Unit, Birmingham Women's and Children's Hospital, Birmingham, UK

⁷Department of Histopathology Birmingham Children's Hospital, Birmingham, UK

⁸Institute of Liver Studies, King's College Hospital, London, UK

⁹Department of Cellular Pathology, Royal Free London, London, UK

¹⁰NIHR Health Protection Research Unit in Healthcare Associated Infections and Antimicrobial Resistance, London, UK

¹¹Blood Safety, Hepatitis, STI & HIV Division, UK Health Security Agency, London, UK

¹²Paediatric Liver, GI & Nutrition Centre and Mowat Labs, King's College Hospital, London, UK

¹³Institute of Liver Studies, King's College London, London, UK

¹⁴Department of Paediatric Infectious Diseases & Immunology, Evelina London Children's Hospital, London, UK

¹⁵Faculty of Life Sciences & Medicine, King's College London, London, UK

Correspondence

Helen Callaby, UKHSA Rare and Imported Pathogen Laboratory, Porton Down, London, UK.

Email: helen.callaby@ukhsa.gov.uk

Funding information

None

Abstract

In 2022, there were global reports of increased numbers of acute hepatitis not explained by hepatitis A–E virus infection in children. This manuscript summarises histopathology results from 20 patients in the United Kingdom who underwent liver transplant or had a liver biopsy as part of aetiological investigations. All available histopathological samples were reviewed centrally as part of the outbreak investigation. A working group comprised of infection specialists, hepatologists and histopathologists met virtually to review the cases, presentation, investigations and histopathology. All 20 liver samples had evidence of inflammation without significant interface

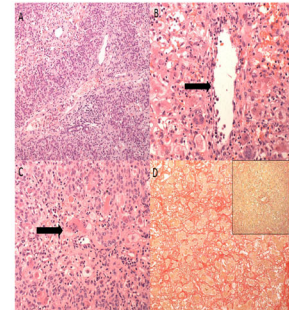
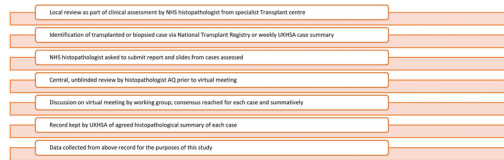
Helen Callaby and Emma McGuire are joint first authors. Tassos Grammatikopoulos and Alicia Demirjian are joint senior authors.

This is an open access article under the terms of the [Creative Commons Attribution-NonCommercial](https://creativecommons.org/licenses/by-nc/4.0/) License, which permits use, distribution and reproduction in any medium, provided the original work is properly cited and is not used for commercial purposes.

© 2024 The Authors. *Journal of Pediatric Gastroenterology and Nutrition* published by Wiley Periodicals LLC on behalf of European Society for Pediatric Gastroenterology, Hepatology, and Nutrition and North American Society for Pediatric Gastroenterology, Hepatology, and Nutrition.

activity, and submassive confluent pan-lobular or multilobular hepatocellular necrosis. Overall, the predominant histopathological findings were of acute nonspecific hepatitis with submassive hepatic necrosis and central vein perivenulitis and endothelitis. Histopathological findings were a poor indicator of aetiology.

Is histopathology a good indicator of causation of paediatric acute hepatitis of unknown aetiology 2022?



This review describes the centralised approach to histopathological examination and summarises the findings. Whilst adenovirus was frequently detected in blood or stool, histopathological examination could not support it as a causative factor.

Histopathological findings from the investigation of paediatric acute hepatitis of unknown aetiology, UK 2022. Callaby et al. (2023)

JPGN
Journal of Pediatric Gastroenterology and Nutrition

KEYWORDS

hepatitis, histopathology, liver failure, paediatric, transplant

1 | INTRODUCTION

In April 2022, an unexpectedly high number of cases of acute hepatitis not explained by hepatitis A–E virus infection in children were reported in Scotland. The United Kingdom Health Security Agency (UKHSA) launched a national public health investigation. By July 2022, 35 countries reported 1010 probable cases.¹

As of 19 July 2022, 270 confirmed cases in England were reported to UKHSA² (defined as ‘presenting since 1 January 2022 with an acute hepatitis which is not due to hepatitis A–E viruses, or an expected presentation of metabolic, inherited or genetic, congenital or mechanical cause with serum transaminase greater than 500 IU/L who is 10 years old and under’).² Adeno-associated virus 2 (AAV2) was detected within plasma and ballooned hepatocytes in liver biopsy samples in a subset of cases, alongside a specific human leucocyte antigen (HLA) class II *HLA-DRB1*04:01* allele.³ AAV2 DNA complexes suggesting both adenovirus HAdV-mediated and human herpesvirus 6B (HHV-6B)-mediated replication were also detected in histopathological samples from another subset of cases, with possible AAV2 replication products triggering immune-mediated liver disease in these genetically predisposed children.⁴

Here, we summarise histopathology results from 20 children in England who underwent liver transplant (LT) or had a liver biopsy as part of aetiological investigations. It should be noted that in the United

What is Known

- Adenovirus is implicated in the outbreak of acute hepatitis in children.
- Genomic studies have found high levels of adeno-associated virus 2 DNA in the blood and liver of a high proportion of cases.
- Of histopathology findings that have previously been published, there has not been evidence of adenovirus in hepatocytes.

What is New

- Whilst adenovirus was frequently detected in blood or stool, histopathological examination could not confirm it as a causative factor.
- Histopathological findings were of acute nonspecific hepatitis with submassive hepatic necrosis and central vein perivenulitis and endothelitis.
- Immediate access to the relevant information about the histopathological features observed in this hepatitis outbreak.

Kingdom, paediatric liver transplants are only performed in England. Therefore, the cases may have presented to Wales, Scotland, or Northern Ireland, but any transplant would be undertaken in England.

2 | METHODS

All available histopathological samples were reviewed centrally as part of the outbreak investigation. Sixteen transplanted cases were identified via the UK National Transplant Register, and four additional biopsy samples were identified via weekly case summaries submitted to UKHSA. This report summarises the histological findings from these samples, to provide awareness and commonalities to clinicians worldwide who may identify such cases. The review was not done as part of a trial or research approach and as such ethical approval was not required.

A working group comprised of infection specialists, hepatologists and histopathologists from the three paediatric LT centres (King's College Hospital in London, Leeds General Infirmary and Birmingham Children's Hospital) met virtually to review the cases, presentation, investigations and histopathology. Slides from the cases were shared. An external liver histopathologist (Alberto Quaglia) carried out central peer-review to confirm initial observations. Clinical details of 12 of these cases have been reported.^{5,6}

3 | RESULTS

Among these 20 cases, the median age at presentation was 2.9 years (range 0–6 years), 10 (50%) were female. Of the 16 who underwent LT, the median age was 2.8 years (range 0–6 years) and 7 (43.8%) were female. All 20 liver samples had evidence of inflammation without significant interface activity, and submassive confluent

pan-lobular or multilobular hepatocellular necrosis with only one non-LT case showing minimal hepatocellular necrosis. The inflammation was variable inflammatory infiltrate, largely comprising lymphocytes 14/20 (70%) of specimens showed endotheliitis and perivenulitis of central veins. Established hepatic fibrosis was present in a minority 2/20 (10%) comprising peri-sinusoidal and portal fibrosis in a single patient 1/20 (5%) and portal fibrosis alone 1/20 (5%) in another. Viral inclusion bodies were not identified in any specimens (Figure 1).

When commenting on possible aetiology, a broad differential was hypothesised, including viral infection, toxin-related injury and acute presentation of autoimmune hepatitis, although the latter was not strongly favoured. In the two with true fibrosis, an acute on chronic or subacute injury was likely: one case was diagnosed with alpha-1-antitrypsin deficiency; in the other, the aetiology underlying the fibrosis was not identified. The pattern of necrosis noted in both biopsy and LT specimens was not of the type observed in cases of adenovirus-related hepatitis in immunocompromised patients and mimicking herpes virus-related hepatitis.⁷ Drug-induced liver injury has also been speculated as a cause of hepatic failure⁸

Central vein changes are often observed in livers with severe acute injury, particularly in livers removed at transplantation, irrespective of whether the aetiology is drug, virus, autoimmunity-related, or indeterminate. Typical changes of sinusoidal obstruction syndrome were not observed in our cases.⁹

Given the high levels of adenovirus noted in cases, adenovirus-specific staining was done in 12/20 (60%) of cases and this was negative in all. Adenovirus in blood,

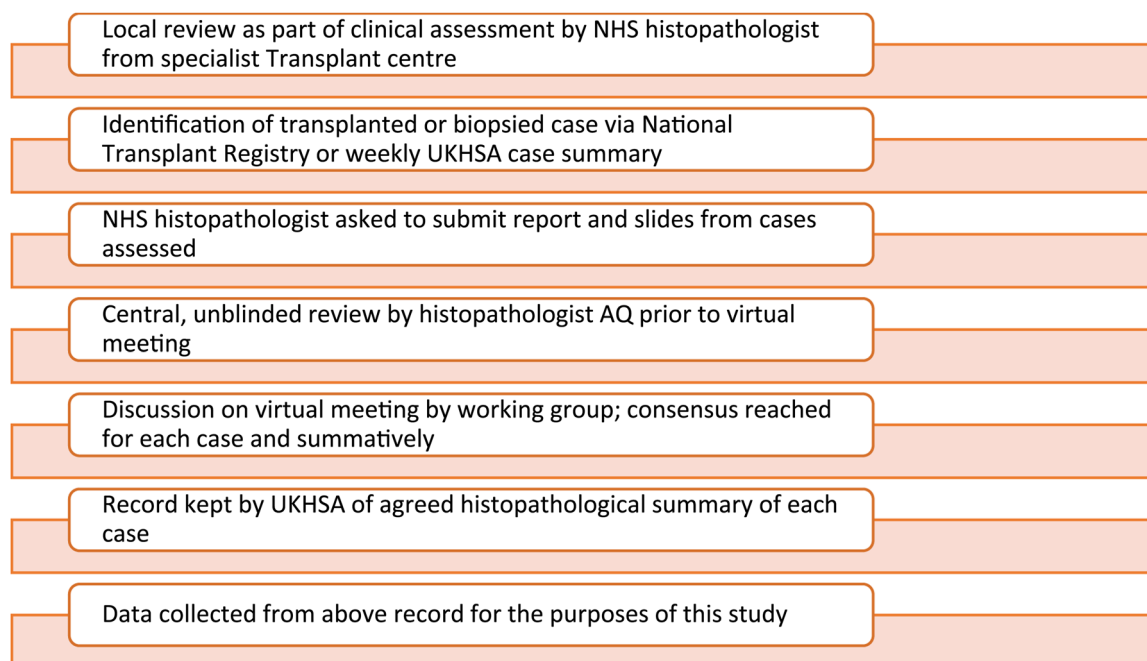


FIGURE 1 Process of histopathological review by working group.

tested by polymerase chain reaction (PCR), was detectable in 15/16 (93.8%) LT cases. In one case where adenovirus was not detected in blood, it was also negative in throat and stool samples.

Six cases who underwent LT had liver tissue tested by adenovirus PCR at a UKHSA laboratory. Four of these were PCR positive and all four were identified as human adenovirus 41 (HadV-F41). As liver tissue is highly vascular, it is unclear if this reflects virus presence in liver tissue or in blood. Metagenomic testing of liver tissue in these same four cases also identified AAV-2 and HHV-6.³

No direct cytopathic effect in keeping with acute viral infection was observed, albeit histology alone does not exclude this. It is not possible, based on the histopathological features, to determine whether the detectable virus contributed directly to the observed pathology or represented reactivation during acute viral infection or liver injury.

Overall, the predominant histopathological findings were of acute nonspecific hepatitis with submassive

hepatic necrosis and central vein perivenulitis and endotheliitis. Histopathological findings were a poor indicator of aetiology in this series.

4 | CONCLUSION

These 20 cases are likely to have a more severe course, however, as these children manifested the most severe spectrum of illness, it would have been reasonable to expect to find more specific and clinically relevant findings on histopathology.

This report provides immediate access to the relevant histopathological features observed in this hepatitis outbreak and provides a framework for future reference to a working group-based approach to the histopathological evaluation of tissue injury.

The centralised approach to histopathological examination summarises the findings as acute non-specific hepatitis with submassive hepatic necrosis and central vein perivenulitis and endotheliitis. Whilst

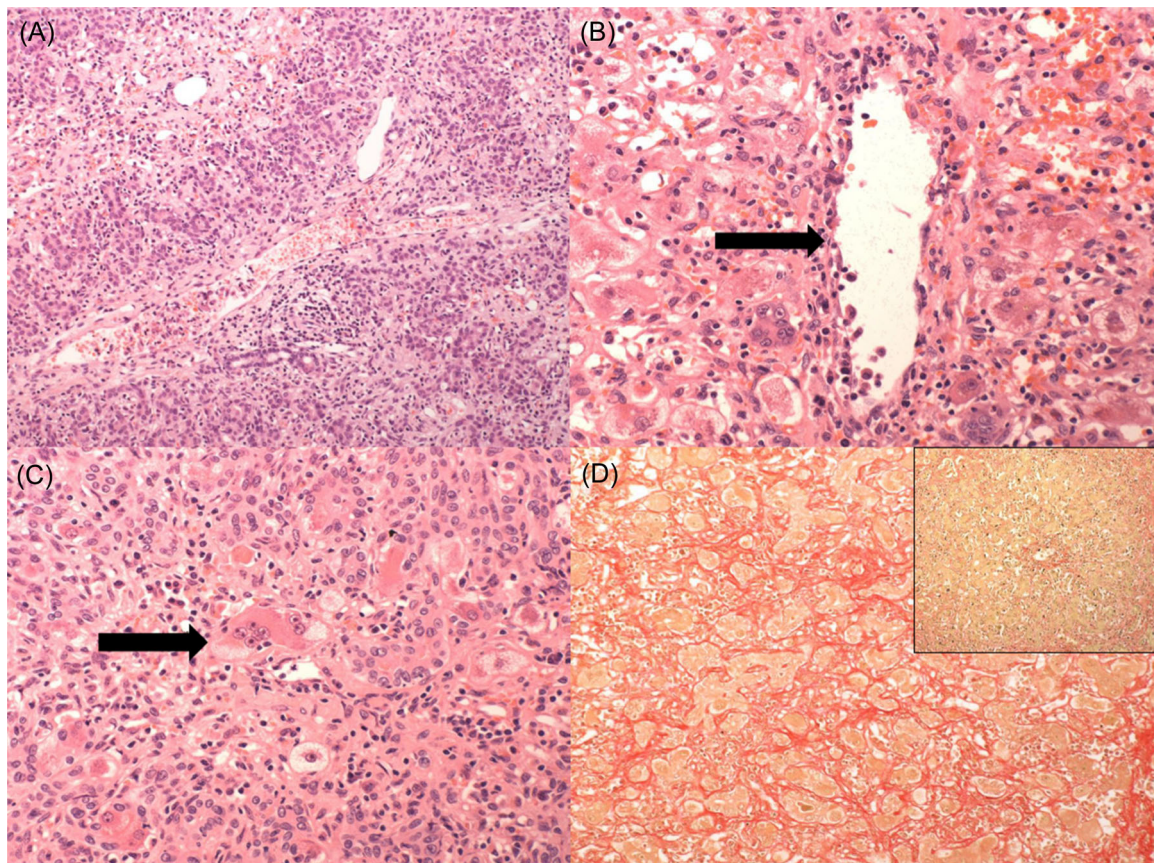


FIGURE 2 The predominant histology was that of acute nonspecific cholestatic hepatitis (A, H&E $\times 100$ magnification) with submassive hepatocellular necrosis. Varying degrees of porto-lobular inflammation were present, without significant interface activity. Endotheliitis affecting the central vein (B, H&E $\times 200$ magnification, black arrow) as well as perivenulitis and hepatocyte giant cell change were present (C, H&E $\times 200$ magnification, black arrow) in the majority of cases. Reported features typical for adenovirus infection were not seen. No significant fibrosis was seen, with the exception of two cases, one of which demonstrated portal and peri-sinusoidal fibrosis (D, Picro Sirius Red $\times 200$ main image vs an explant with no significant fibrosis, inset Picro Sirius Red $\times 100$ magnification) and one other demonstrated portal fibrosis alone. Due to the degree of hepatocellular necrosis, it was not possible to comment on an aetiology underlying the fibrosis.

adenovirus was frequently detected in blood or stool, histopathological examination could not confirm it as a causative factor (Figure 2).

ACKNOWLEDGEMENTS

Judith Breuer, The UKHSA Hepatitis of unknown aetiology in children Incident Management Team. The authors have indicated they have no financial relationships relevant to this article to disclose.

CONFLICT OF INTEREST STATEMENT

The authors declare no conflict of interest.

REFERENCES

1. WHO. *Acute Hepatitis of Unknown Aetiology in Children—Multicountry*. WHO; 2022. <https://www.who.int/emergencies/disease-outbreak-news/item/2022-DON400>
2. United Kingdom Health Security Agency. *Investigation into Acute Hepatitis of Unknown Aetiology in Children in England Technical Briefing 4*. United Kingdom Health Security Agency; 2022. https://assets.publishing.service.gov.uk/government/uploads/system/uploads/attachment_data/file/1094573/acute-hepatitis-technical-briefing-4.pdf
3. Ho A, Orton R, Tayler R, et al. Adeno-associated virus 2 infection in children with non-A–E hepatitis. *Nature*. 2023; 617(7961):555-563.
4. Morfopoulou S, Buddle S, Torres Montaguth OE, et al. Genomic investigations of unexplained acute hepatitis in children. *Nature*. 2023;617(7961):564-573.
5. Kelgeri C, Couper M, Gupte GL, et al. Clinical spectrum of children with acute hepatitis of unknown cause. *N Engl J Med*. 2022;387(7):611-619.
6. Deep A, Grammatikopoulos T, Heaton N, Verma A, Dhawan A. Outbreak of hepatitis in children: clinical course of children with acute liver failure admitted to the intensive care unit. *Intensive Care Med*. 2022;48(7):958-962.
7. Ronan BA, Agrwal N, Carey EJ, et al. Fulminant hepatitis due to human adenovirus. *Infection*. 2014;42(1):105-111.
8. Fischler B, Mandato C, Vajro P. The debate on paracetamol hepatotoxicity continues. *Acta Paediatr (Stockholm)*. 2024; 113(1):15-18.
9. Kleiner DE. Recent advances in the histopathology of drug-induced liver injury. *Surg Pathol Clin*. 2018;11(2):297-311.

How to cite this article: Callaby H, McGuire E, Rajwal S, et al. Histopathological findings from the investigation of paediatric acute hepatitis of unknown aetiology, United Kingdom 2022. *J Pediatr Gastroenterol Nutr*. 2024;78:534-538. doi:10.1002/jpn3.12133